«Νεότερες εξελίξεις στη βρογχοσκοπική προσπέλαση περιφερικών πνευμονικών όζων».

ΚΟΝΤΟΠΥΡΓΙΑΣ ΓΕΩΡΓΙΟΣ

ΠΝΕΥΜΟΝΟΛΟΓΟΣ MD, MSc, FCCP

ΝΟΣΟΚΟΜΕΙΟ METROPOLITAN

Δήλωση σύγκρουσης συμφερόντων

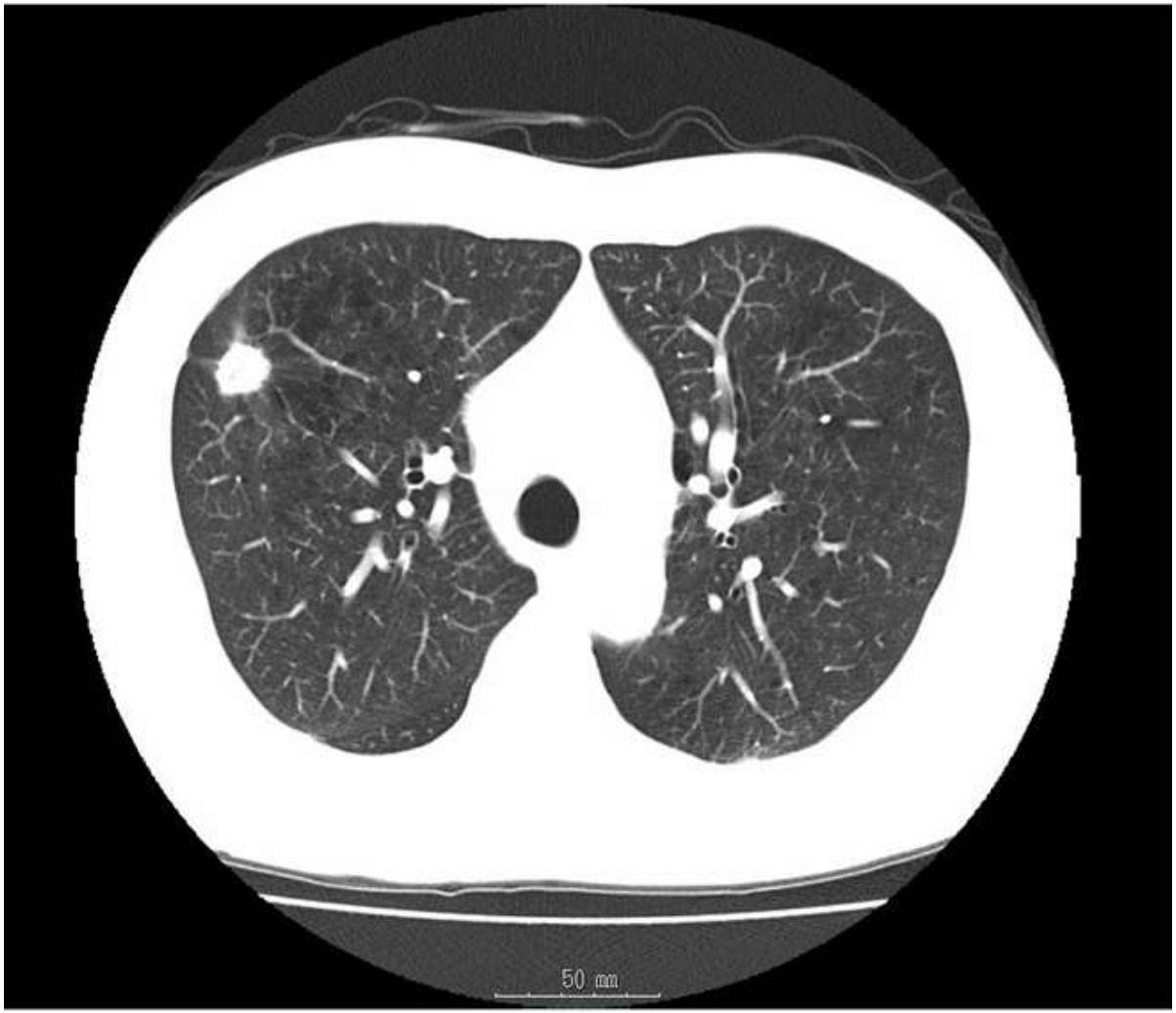
50 mm

Βιοψία υπό αξονικό τομογράφο

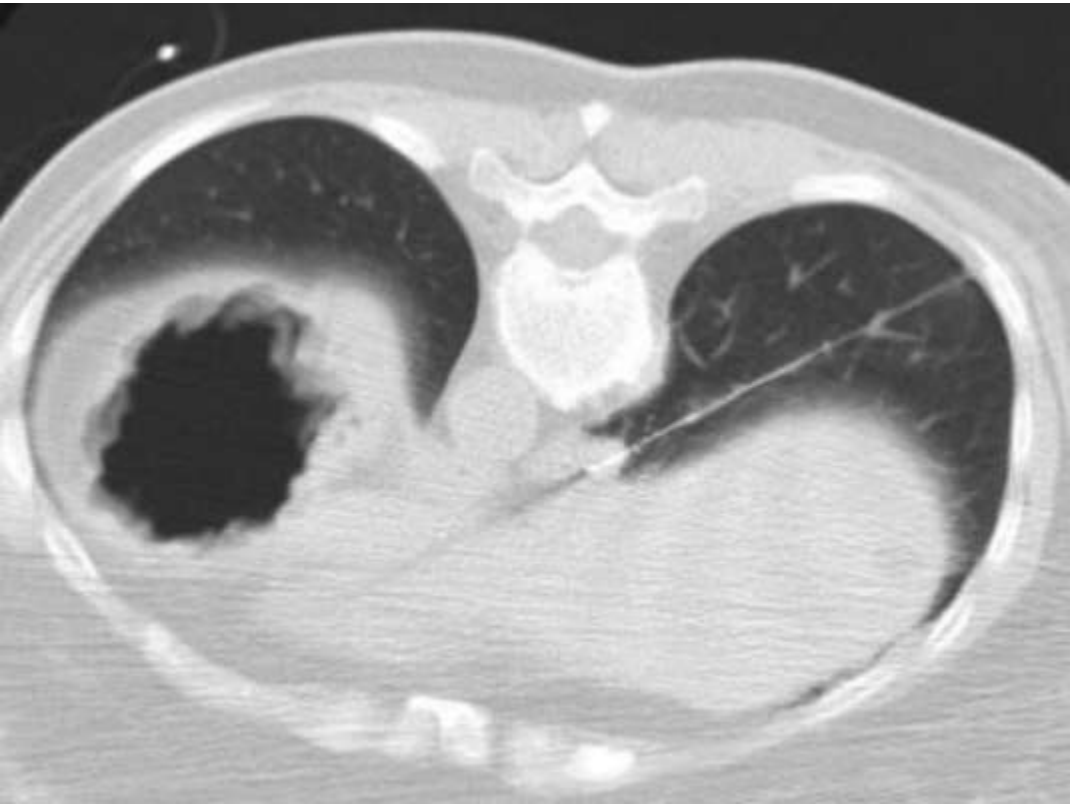

CT-FNB

Ευαισθησία 90%

(Ευαισθησία 74–88% $\leq$ 15 mm)

Πνευμοθώρακας 20- 25%
(μέγεθος, απόσταση, παθολογία)

M Cham et al Semin Respir Crit Care Med 2008

Διάγνωση περιφερικής βλάβης

Διαβρογχική βιοψία (υπό ακτινοσκόπηση)

- Δεν παρέχει αίσθηση βάθους (2D απεικόνιση)
- Δυσχερής εντοπισμός βλάβης

Διάγνωση περιφερικής βλάβης

Βρογχοκυψελιδικό έκπλυμα

Υπό ακτινοσκόπηση

Περιφερικό brushing

Παρακέντηση με βελόνα

Διάγνωση περιφερικής βλάβης

Ευαισθησία 78%

(TBB 57%, Brush 54%, BAL 43%, TBNA 65%)

Table 3—*Sensitivity of FB Diagnostic Procedures for Peripheral Bronchogenic Carcinoma*

		Sensitivity				
Study/Year	Patients,* No.	All Methods	Transbronchial Biopsy	Brush	BAL	TBNA
Summary	5,742	0.78	0.57	0.54	0.43	0.65

Diagnosis and Management of Lung Cancer: ACCP Guidelines 2013

Διάγνωση περιφερικής βλάβης

Ευαισθησία 78%

(TBB 57%, Brush 54%, BAL 43%, TBNA 65%)

Table 3—*Sensitivity of FB Diagnostic Procedures for Peripheral Bronchogenic Carcinoma*

		Sensitivity				
Study/Year	Patients,* No.	All Methods	Transbronchial Biopsy	Brush	BAL	TBNA
Summary	5,742	0.78	0.57	0.54	0.43	0.65

< 2 cm 34%

> 2 cm 63%

Diagnosis and Management of Lung Cancer: ACCP Guidelines 2013

BELUGA AIRBUS
1

ΠΕΡΙΦΕΡΙΚΕΣ ΒΛΑΒΕΣ

Επιβεβαίωση θέσης

Καθοδήγηση

ΠΕΡΙΦΕΡΙΚΕΣ ΒΛΑΒΕΣ
Επιβεβαίωση θέσης
Καθοδήγηση

Ενδοβρογχικό υπερηχογράφημα

Radial endobronchial ultrasound (rEBUS)



rEBUS

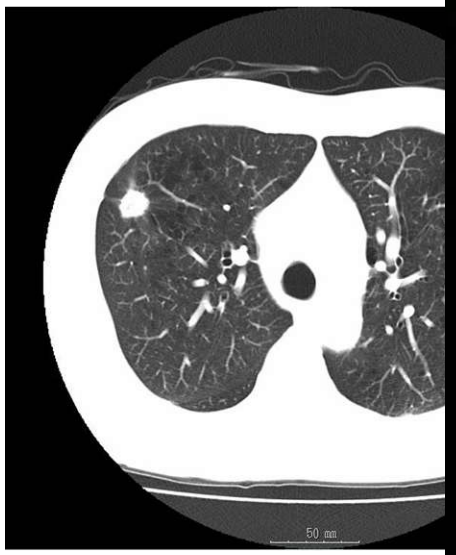
50 mm

ID:
NAME:
SEX: AGE:
DOB: / /
2011/01/26
15:26:42
FREQ : 20MHz
RANGE: 4Cm
GAIN : 8
CONT : 3
IMAGE:NORMAL
STC:
0.0
1.0
2.0
3.0 Cm
SCALE: 5mm
DIR :INVERSE

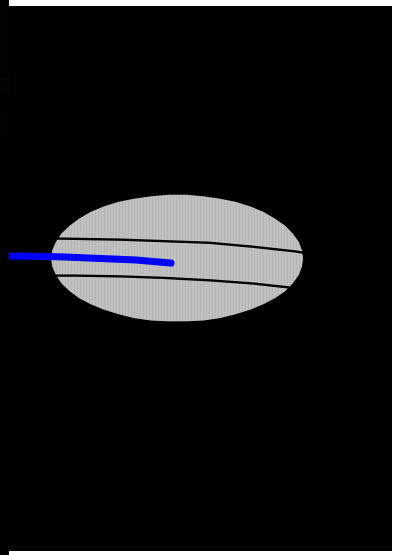

rEBUS

Endobronchial ultrasound-guided transbronchial lung biopsy in solitary pulmonary nodules and peripheral lesions

F.J.F. Herth*, A. Ernst#, H.D. Becker*

- EBUS SPN<3cm (80% vs 57%)
- Πνευμοθώρακας 1.4% fluoroscopy-TBBX
- EBUS: όχι επιπλοκές, όχι ακτινοβολία

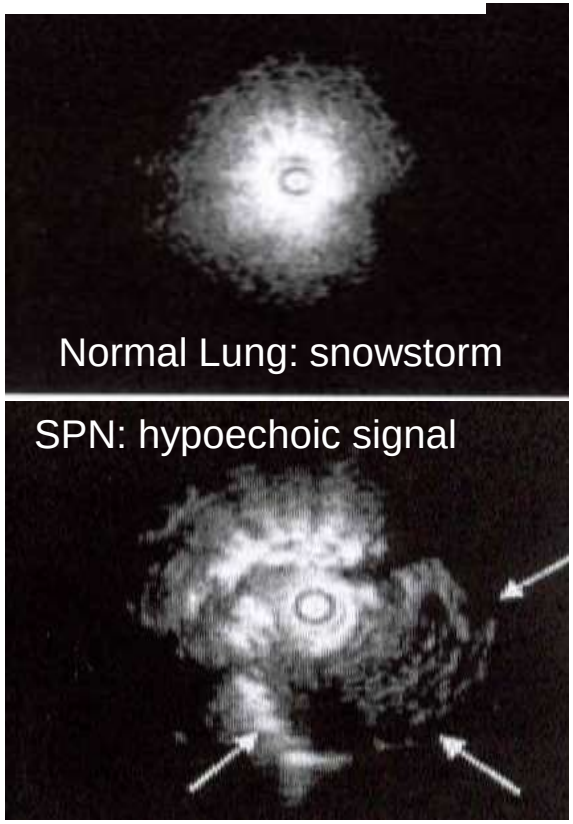

Herth et al. ERJ 2002

rEBUS

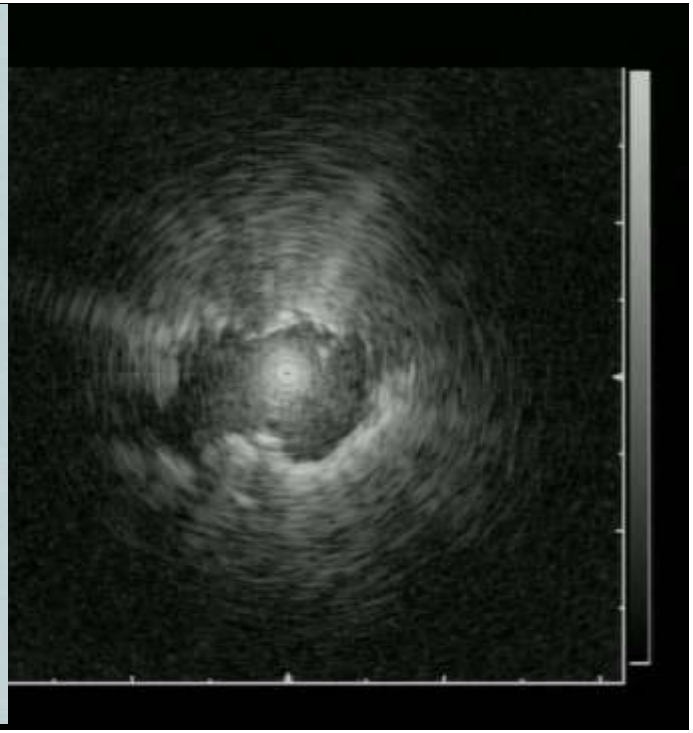

rEBUS + guided sheath

Endobronchial Ultrasonography Using a Guide Sheath Increases the Ability To Diagnose Peripheral Pulmonary Lesions Endoscopically*

Noriaki Kurimoto, MD; Teruomi Miyazawa, MD, FCCP; Seiji Okimasa, MD;

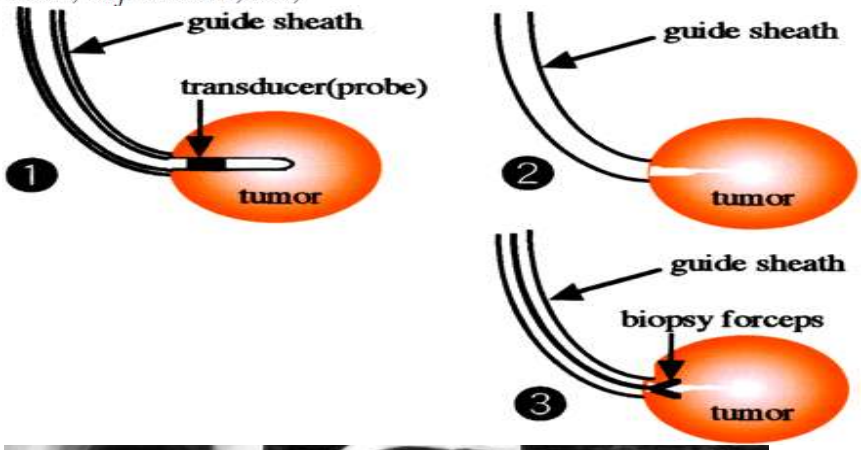

- Yield 77%,

(κακοήθεις 81%, καλοήθεις 69%)

- Όζοι ≤10mm, yield= 76%
- Probe 87% εντόπιση όζου
- + ακτινοσκόπηση

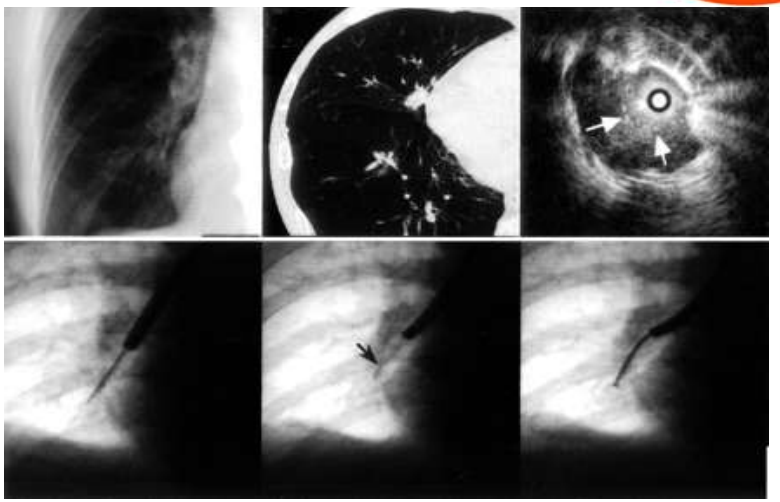

Kurimoto et al. Chest 2004

ΠΕΡΙΦΕΡΙΚΕΣ ΒΛΑΒΕΣ

Επιβεβαίωση θέσης

Καθοδήγηση

Ηλεκτρομαγνητική καθοδήγηση (electromagnetic navigation bronchoscopy, ENB)

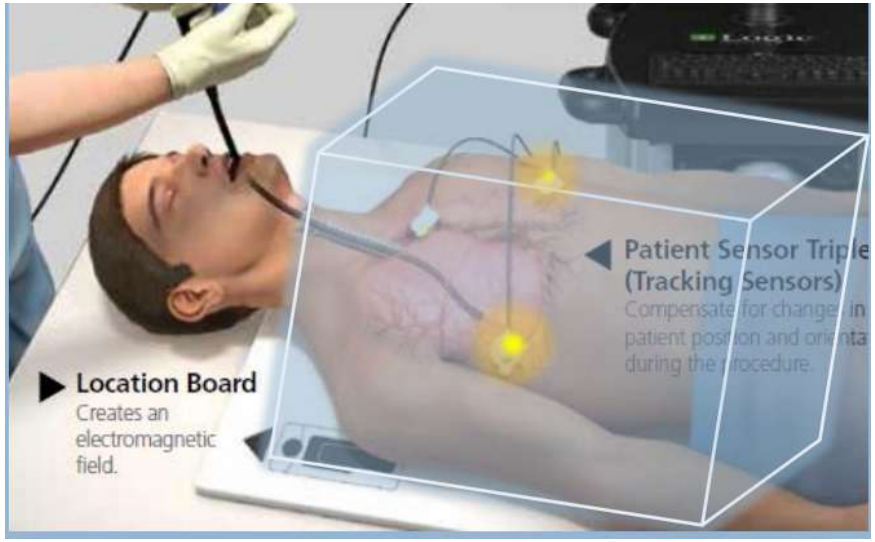

Βρογχοσκόπηση εντός μαγνητικού πεδίου

Αισθητήρας θέσης

Εκτεταμένο κανάλι εργασίας

Ηλεκτρομαγνητική καθοδήγηση (electromagnetic navigation bronchoscopy, ENB)

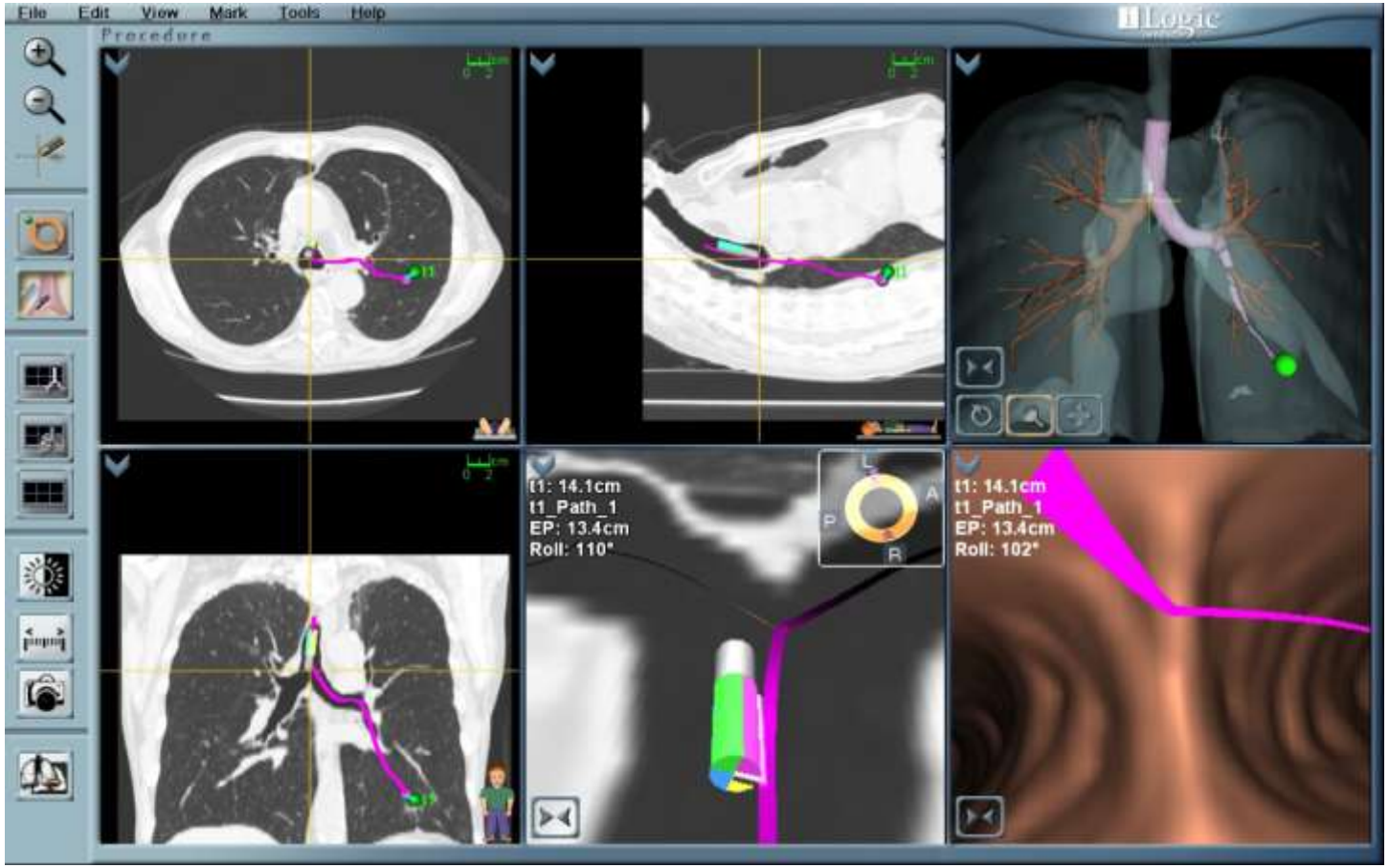

Ηλεκτρομαγνητική καθοδήγηση (electromagnetic navigation bronchoscopy, ENB)

Ηλεκτρομαγνητική καθοδήγηση (electromagnetic navigation bronchoscopy, ENB)

- ENB yield 71 %
- Πνευμοθώρακας : 4%

Rivera et al Diagnosis and Management of Lung Cancer: ACCP Guidelines 2013

ΠΕΡΙΦΕΡΙΚΕΣ ΒΛΑΒΕΣ

Επιβεβαίωση θέσης

+

Καθοδήγηση

Ηλεκτρομαγνητική καθοδήγηση + rEBUS

- ENB yield 71 %
- Πνευμοθώρακας : 4%

Rivera et al Diagnosis and Management of Lung Cancer: ACCP Guidelines 2013

	EBUS, n (%)	ENB, n (%)	EBUS and ENB, n (%)	p
yield	27/39 (69	23/39 (59	35/40 (88	0.02*

Eberhardt et al AJRCCM 2007

Διάγνωση περιφερικής βλάβης

3.3.2.1. In patients suspected of having lung cancer, who have a peripheral lung nodule, and a tissue diagnosis is required due to uncertainty of diagnosis or poor surgical candidacy, radial EBUS is recommended as an adjunct imaging modality (Grade 1C).

Remark: Radial EBUS can confirm in real time the ideal location of bronchoscopic sampling and increase the diagnostic yield over conventional bronchoscopy for peripheral nodules.

3.4.2.1. In patients with peripheral lung lesions difficult to reach with conventional bronchoscopy, electromagnetic navigation guidance is recommended if the equipment and the expertise are available (Grade 1C).

Remark: The procedure can be performed with or without fluoroscopic guidance and it has been found complementary to radial probe ultrasound

Diagnosis and Management of Lung Cancer: ACCP Guidelines 2013

BELUGA AIRBUS
2
VIA 9GAG.COM

Καθοδήγηση με εικονική βρογχοσκόπηση (virtual broncoscopic navigation, VBN)

Λεπτά βρογχοσκόπια (d=4.2mm)

Υπέρλεπτα βρογχοσκόπια (d=2.8mm 3.5mm)

Έως 9ης γενιάς βρόγχους

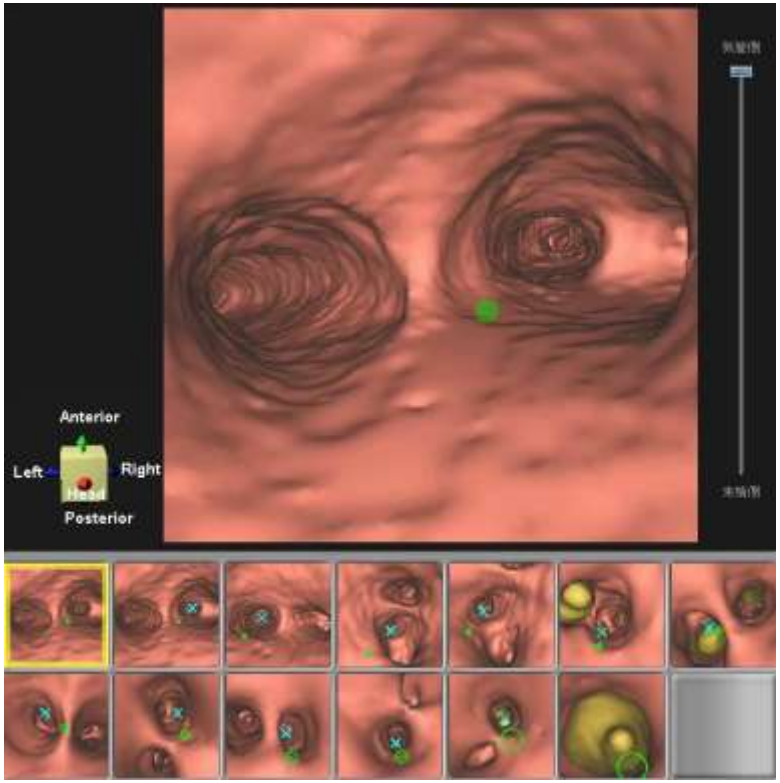

Καθοδήγηση με εικονική βρογχοσκόπηση (virtual broncoscopic navigation, VBN)

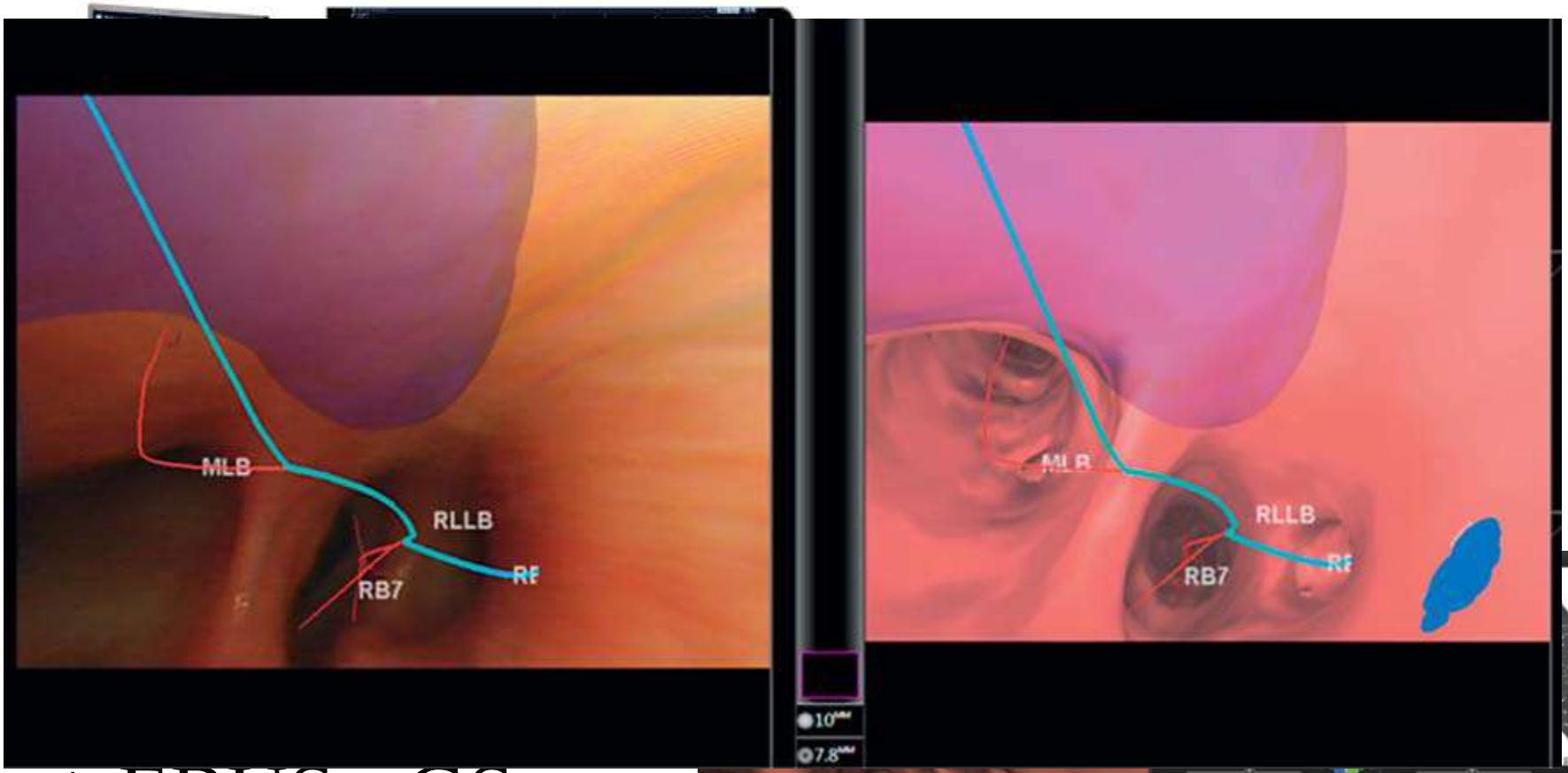

± EBUS - GS

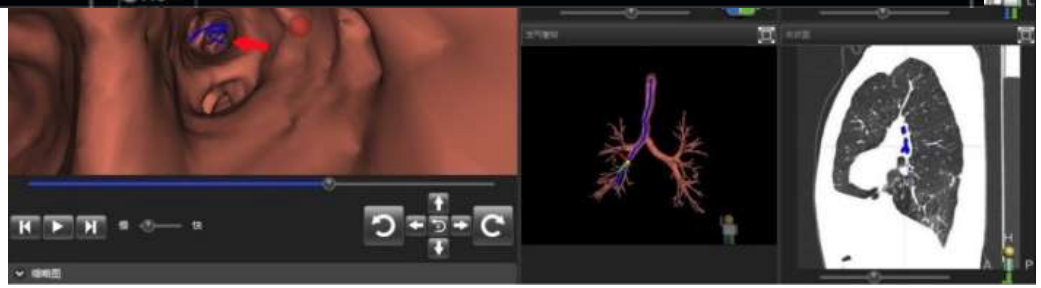

CHEST

Original Research

PULMONARY PROCEDURES

Meta-analysis of Guided Bronchoscopy for the Evaluation of the Pulmonary Nodule

Jessica S. Wang Memoli, MD; Paul J. Nietert, PhD; and Gerard A. Silvestri, MD, FCCP

Wang Memoli JS et al CHEST 2012; 142(2):385–393

CHEST Original Research
PULMONARY PROCEDURES

Meta-analysis of Guided Bronchoscopy for the Evaluation of the Pulmonary Nodule

Jessica S. Wang Memoli, MD; Paul J. Nietert, PhD; and Gerard A. Silvestri, MD, FCCP

Table 2—*Inverse Weighted Diagnostic Yield Overall and by Modality*

Technology	Studies, No.	Weighted Proportion, %	95% CI	Q Statistic	Q *P* Value
VB	10	72.0	(65.7-78.4)	21.0	.01
ENB	11	67.0	(62.6-71.4)	13.3	.21
GS	10	73.2	(64.4-81.9)	63.8	<.0001
U	11	70.0	(65.0-75.1)	15.2	.12
R-EBUS	20	71.1	(66.5-75.7)	84.2	<.0001
All	39	70.0	(67.1-72.9)	119.4	<.0001

< 2 cm 34% ➔ 61%

> 2 cm 63% ➔ 82%

Wang Memoli JS et al CHEST 2012; 142(2):385–393

Bangkok Air
Bangkok Air
Bangkok Air
Bangkok Air
HS-PGV

Diagnostic Yield and Complications of Bronchoscopy for Peripheral Lung Lesions

Results of the AQuIRE Registry

15 κέντρα 22 ιατροί 312 ασθ

AQUIRE 2016 PPN < 2 CM

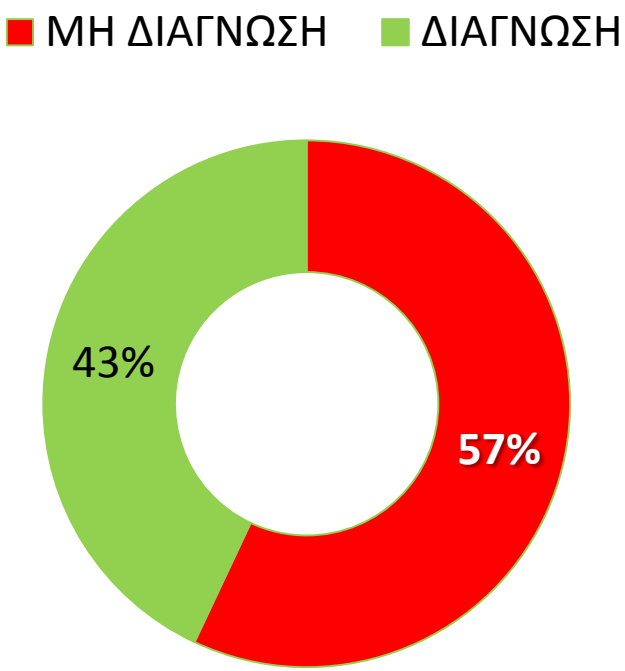

Am J Respir Crit Care Med. 2016 Jan 1; 193(1): 68–77.

Diagnostic Yield and Complications of Bronchoscopy for Peripheral Lung Lesions

David E. Ost[1], Armin Ernst[2], Xiudong Lei[3], Kevin L. Kovitz[4], Sadia Benzaquen[5], Javier Diaz-Mendoza[6], Sara Greenhill[6], Jennifer Toth[7], David Feller-Kopman[8], Jonathan Puchalski[9], Daniel Baram[10], Raj Karunakara[11], Carlos A. Jimenez[1], Joshua J. Filner[12], Rodolfo C. Morice[1], George A. Eapen[1], Gaetane C. Michaud[9], Rosa M. Estrada-Y-Martin[13], Samaan Rafeq[2], Horiana B. Grosu[1], Cynthia Ray[6], Christopher R. Gilbert[7], Lonny B. Yarmus[8], and Michael Simoff[6]; on behalf of the AQuIRE Bronchoscopy Registry

[1]Department of Pulmonary Medicine and [3]Department of Biostatistics, The University of Texas MD Anderson Cancer Center, Houston, Texas; [2]Department of Pulmonary and Critical Care Medicine, St. Elizabeth's Medical Center, Boston, Massachusetts; [4]Chicago Chest Center, Chicago, Illinois; [5]University Hospital of Cincinnati Veteran Affairs Medical Center, Cincinnati, Ohio; [6]Henry Ford Hospital, Detroit, Michigan; [7]Milton S. Hershey Medical Center, Hershey, Pennsylvania; [8]John Hopkins Hospital, Baltimore, Maryland; [9]Yale New Haven Hospital, New Haven, Connecticut; [10]Mather Memorial Hospital, Port Jefferson, New York; [11]Munroe Regional Medical Center, Ocala, Florida; [12]Kaiser Sunnyside Medical Center, Clackamas, Oregon; and [13]Lyndon B. Johnson Hospital–The University of Texas Health Science Center Houston, Houston, Texas

Yield 54% (33% - 73%)

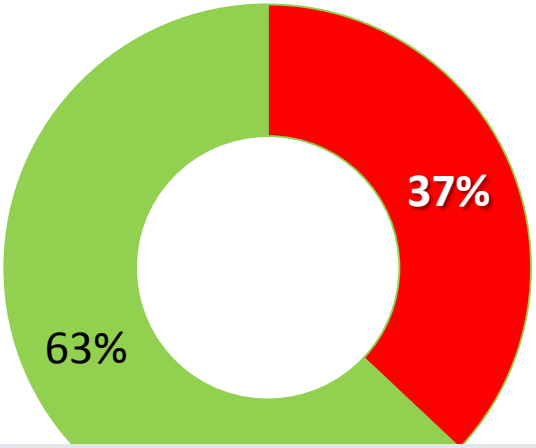

No rEBUS/EMN	64%
rEBUS	57%
EMN	38%
rEBUS/EMN	47%

Conclusions: Peripheral TBNA improved diagnostic yield for peripheral lesions but was underused. The diagnostic yields of EMN and r-EBUS were lower than expected, even after adjustment.

Am J Respir Crit Care Med. 2016 Jan 1; 193(1): 68–77.

ORIGINAL ARTICLE

A Bronchial Genomic Classifier for the Diagnostic Evaluation of Lung Cancer

Gerard A. Silvestri, M.D., Anil Vachani, M.D., Duncan Whitney, Ph.D., Michael Elashoff, Ph.D., Kate Porta Smith, M.P.H., J. Scott Ferguson, M.D., Ed Parsons, Ph.D., Nandita Mitra, Ph.D., Jerome Brody, M.D., Marc E. Lenburg, Ph.D., and Avrum Spira, M.D., for the AEGIS Study Team*

Total Bronchoscopy (n = 687)

- **Standard (n = 249)**
- **EMN (n = 23)**
- **EBUS (n = 306)**
- **Combination (n = 109)**

28 sites 639 patients	Overall – 53% for diagnosis of cancer

N Engl J Med 2015;373:243-51.

Standard Bronchoscopy With Fluoroscopy vs Thin Bronchoscopy and Radial Endobronchial Ultrasound for Biopsy of Pulmonary Lesions

A Multicenter, Prospective, Randomized Trial

Nichole T. Tanner, MD; Lonny Yarmus, DO; Alexander Chen, MD; Jessica Wang Memoli, MD; Hiren J. Mehta, MD; Nicholas J. Pastis, MD; Hans Lee, MD; Michael A. Jantz, MD; Paul J. Nietert, PhD; and Gerard A. Silvestri, MD

5 sites 221 patients	Overall – 44% SB-F – 37% TB-EBUS – 49%

Chest. 2018 Nov;154(5):1035-1043

Aero Republica

J Thorac Oncol. 2018 Nov 23. pii: S1556-0864(18)33456-7. doi: 10.1016/j.jtho.2018.11.013. [Epub ahead of print]

Electromagnetic Navigation Bronchoscopy for Peripheral Pulmonary Lesions: One-Year Results of the Prospective, Multicenter NAVIGATE Study.

Folch EE[1], Pritchett MA[2], Nead MA[3], Bowling MR[4], Murgu SD[5], Krimsky WS[6], Murillo BA[7], LeMense GP[8], Minnich DJ[9], Bansal S[10], Ellis BQ[11], Mahajan AK[12], Gildea TR[13], Bechara RI[14], Sztejman E[15], Flandes J[16], Rickman OB[17], Benzaquen S[18], Hogarth DK[19], Linden PA[20], Wahidi MM[21], Mattingley JS[22], Hood KL[23], Lin H[23], Wolvers JJ[23], Khandhar SJ[12]; NAVIGATE Study Investigators.

ΣΤΟΧΟΣ 2.500 ΑΣΘΕΝΕΙΣ

29 ΚΕΝΤΡΑ

- Δείγματα σε 1092/1157 (94%)
- rEBUS 57%
- ENB yield 73% (12 μήνες)
- Κακοήθεια Sn 69% NPV 56%
- Πνευμοθώρακας : 2.9% (παρέμβαση)

ΕΞΕΛΙΞΗ

- Μη ορατές σε fluoro
- Αναπνευστικές κινήσεις
  - όχι real nodule
- Θέση σώματος vs CT
  - όχι real time
- Εργαλεία στην
  - περιφέρεια
- **Σχέση με βρόγχο**
  - **+bronchus sign**

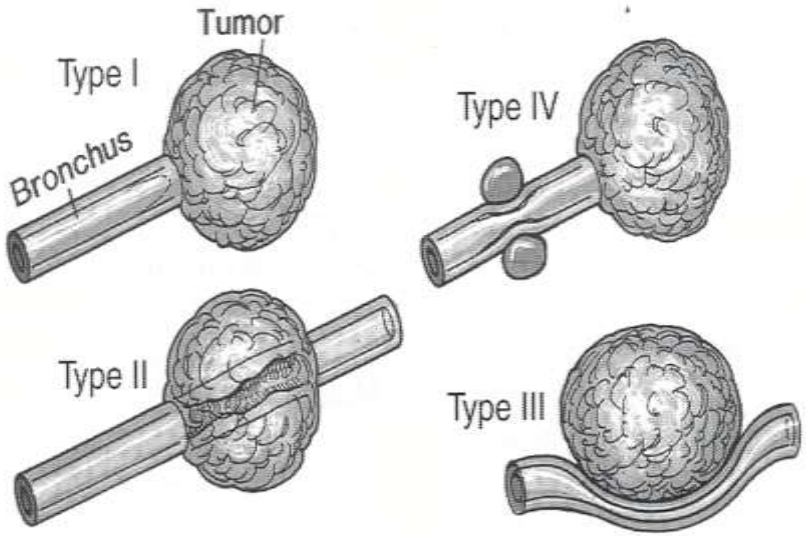

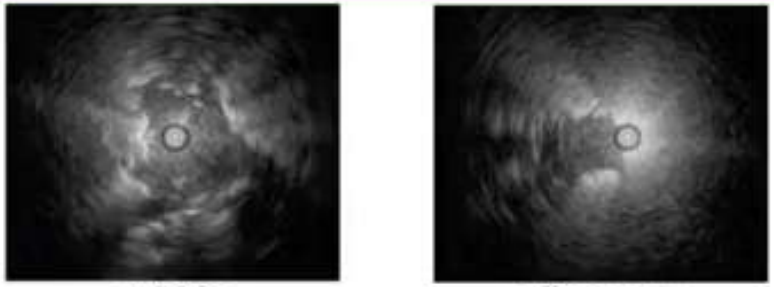

within *adjacent to*

location of the probe	brushing (140)	TBB (110)	total (140)
within (121)	81/121 (67%)	79/96 (82%)	105/121 (87%)
adjacent to (19)	7/19 (37%)	1/14 (7%)	8/19 (42%)

ΕΞΕΛΙΞΗ

Απεικόνιση

Πρόσβαση στις βλάβες

ΕΞΕΛΙΞΗ

Απεικόνιση

Πρόσβαση στις βλάβες

Augmented endobroncial fluoroscopic navigation

Feasibility of the Lungvision Augmented Endobronchial Fluoroscopic Navigation and Localization System: Comparison With Cone Beam CT for Nodule Localization

Michael Pritchett

RESULTS: 20 patients were included in the study with average age of 71.6+SD (range 48-85). Average lesion size was 21.7mm+SD (range 10-33mm), and 70% of the lesions were located in the upper lobes (RUL/LUL). No peri-procedural adverse events were reported. Successful navigation to the pulmonary nodule, according to LungVision display, was achieved in all cases. In 100% of cases (20 out of 20), the lesion size and location shown by the LungVision system matched CBCT imaging (accuracy 5mm+SD). Tissue samples were successfully acquired in all cases.

CONCLUSIONS: Augmented endobronchial fluoroscopic navigation is safe, feasible and provides lesion localization accuracy similar to CBCT-guided endobronchial biopsy.

CHEST Annual Meeting 2017

Oct 2017:152 (4) Suppl A863

Augmented endobroncial fluoroscopic navigation

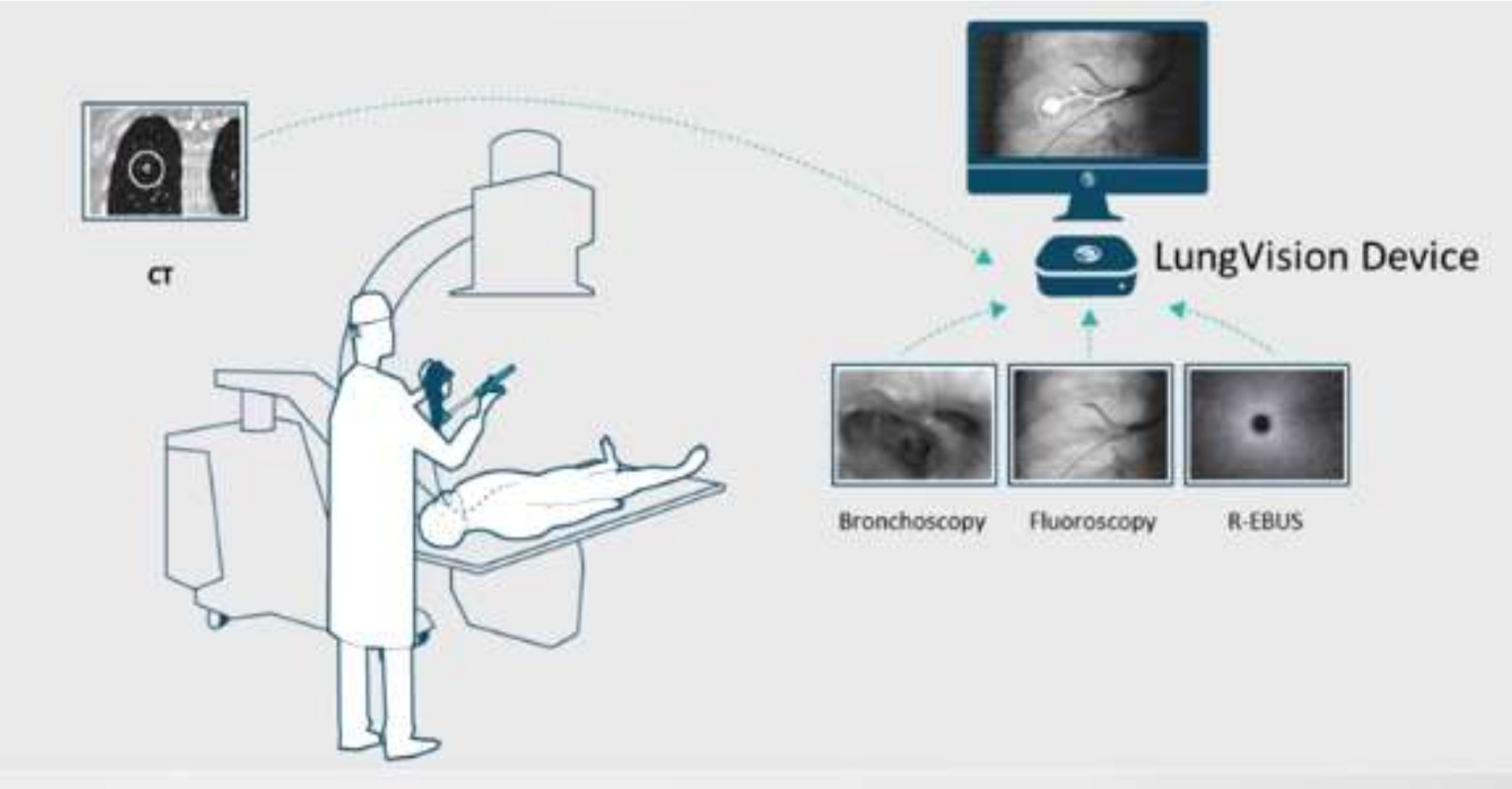

Augmented endobroncial fluoroscopic navigation

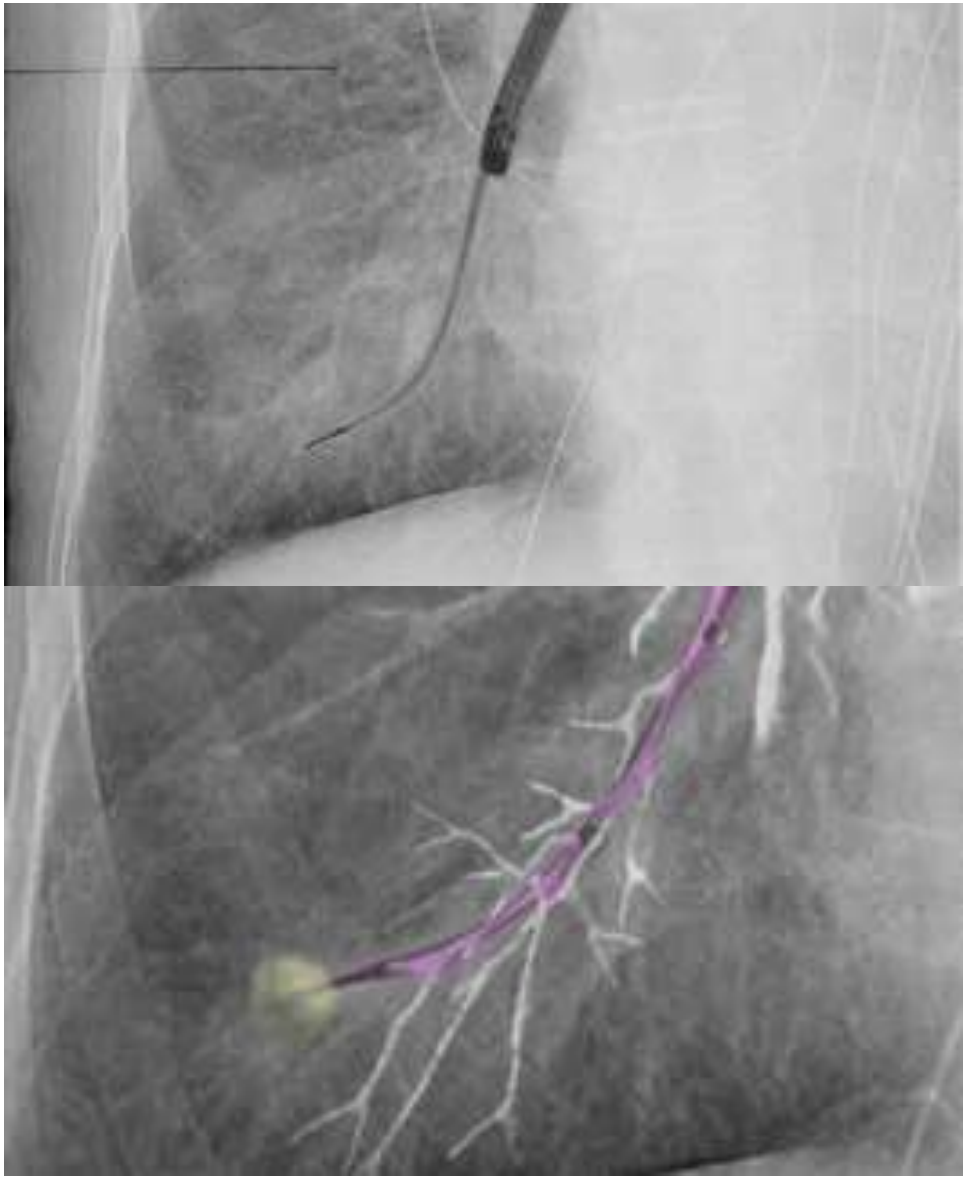

Augmented endobroncial fluoroscopic navigation

Real time – Real nodule

Augmented endobroncial fluoroscopic navigation

A NOVEL ENDOBRONCHIAL FLUOROSCOPIC NAVIGATION AND LOCALIZATION SYSTEM: A SUMMARY OF A MULTICENTER LUNGVISION TRIAL

D. HOGARTH MD, FCCP* THE UNIVERSITY OF CHICAGO

KRISH BHADRA PATRICK WHITTEN AND MICHAEL PRITCHETT

200 ασθενείς 6 κέντρα
PPN 17mm
70% άνω λοβούς
86 % εντοπισμός βλάβης
yield = 78%



CHEST Annual Meeting 2018

October 2018 Volume 154, Issue 4, Suppl 880A–882A

Cone beam CT ± EMN

W Hohenforst-Shmidt et al J Cancer 2014

- av d=2.5 cm (n=33)
- yield 70%

SC Park et al Thorac Cancer 2017

- av d=3.1 cm (n=59)
- yield 71.2%

M Prichett et al J Bronchol Inter Pulmonol 2018

- CBCT + ENB (n=75)
- + augmented fluoro
- av d=1.6 cm
- yield 83.7%

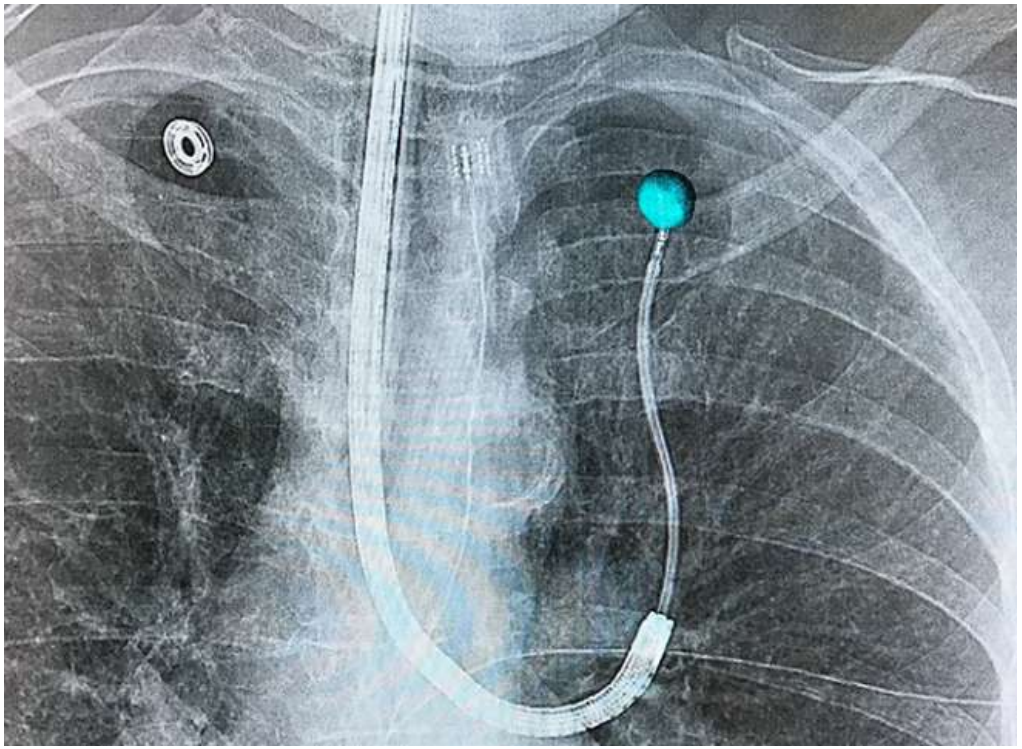

ΕΞΕΛΙΞΗ

Απεικόνιση

Πρόσβαση στις βλάβες

Bronchoscopic TransParenchymal Nodule Access: Evaluation of Safety and Feasibility of Archimedes System

Felix J. Herth , Shiyue Li , Jiayuan Sun , Daniel Nader ,

- Augmented fluoroscopy
- Virtual doppler
- EAST2 study

A. Creating a hole in the airway wall at point-of-entry with the FlexNeedle

B. Dilating the airway wall with the Archimedes Dilation Balloon

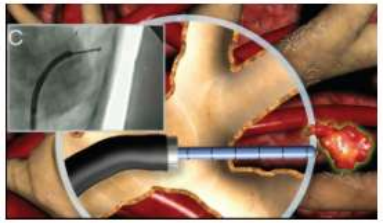

C. Tunnelling with the Archimedes Sheath and blunt stylet through parenchymaltissue using fused fluoroscopic guidance provided by the Archimedes System

D. Accessing sampling and/or treating the nodule with 2mm wording channel compatible bronchoscopic tools

CONCLUSIONS

Low complication risk and competitive process time suggest the benefits of using Archimedes System for BTPNA procedure in both community-based and teaching-based hospitals. There is an ongoing clinical study and more data will be presented to improve statistical confidence.

ATS 2017
Where today's science meets tomorrow's care™

FJ Herth, S Li, J Sun, D Nader; AJRCCM 2017;195:A7597

STAR WARS

Your Eyes Can Deceive You: Don't Trust them

Starring:

Gerard Silvestri
Medical University of South Carolina
Yoda

Hans Lee
Johns Hopkins University
Boba Fett

Nichole Tanner
Medical University of South Carolina
Princess Leia

Alexander Chen
Washington University of St Louis
Strom Trooper

First Human Use of a New Robotic-Assisted Navigation System for Small Peripheral Pulmonary Nodules Demonstrates Good Safety Profile and High Diagnostic Yield

David Fielding, Farzad Bashirzadeh, Jung Hua Son, Maryann Todman, Hau Tan, Adrian Chin, Karin Steinke, Morgan Windsor
Royal Brisbane and Womens Hospital, Brisbane, QLD, Australia

remote controlled 3mm diameter catheter

robotic-assisted catheter remains completely stationary during sampling

a newly developed, investigational flexible biopsy needle

.Overall diagnostic yield for these cases was 83%

CLINICAL IMPLICATIONS: The ability of the catheter and needle to reach distal airways and maintain static position allows unique sampling capability.

CHEST Annual Meeting 2017

Oct 2017:152 (4) Suppl A858

Ρομποτική βρογχοσκόπηση

Εξωτερική διάμετρος 5.7 mm
Τηλεσκοπικό ενδοσκόπιο 4.4 mm (+ 3 γενιές σε σχέση με 4.2 mm)
Συνεχής οπτική επαφή
Σταθερότητα του ενδοσκοπίου κατά τη λήψη δειγμάτων
Σύστημα ηλεκτρομαγνητικής καθοδήγησης

Auris Monarch Surgical Robot to transform lung cancer treatment
https://www.youtube.com/watch?v=qlIiyC3LHx4

MONARCH
LIGHT
PROG.
SNAP

Brand Sentiment 'Hype Cycle' for New Products

Adapted from Jackie Fenn, "When to Leap on the **Hype Cycle**," *Gartner Group*, January 1, 1995

RETURN ON FOCUS

©2006 - 2012 Return on Focus LLC. All rights reserved.
PROPRIETARY AND CONFIDENTIAL

Ευχαριστώ