Διάγνωση και σταδιοποίηση μη μικροκυτταρικού πνευμονικού καρκίνου

ΚΟΝΤΟΠΥΡΓΙΑΣ ΓΕΩΡΓΙΟΣ

ΠΝΕΥΜΟΝΟΛΟΓΟΣ MD, MSc, FCCP

ΝΟΣΟΚΟΜΕΙΟ METROPOLITAN

Δήλωση συμφερόντων

- Γενικά διάγνωσης NSCLC
- Σταδιοποίηση TNM
- Αλγόριθμος σταδιοποίησης
- Κλινικές περιπτώσεις με έμφαση στις βρογχοσκοπικές τεχνικές (παρών και μέλλον)
- Πρώιμη διάγνωση

ΔΙΑΓΝΩΣΗ NSCLC

ΕΠΙΔΗΜΙΟΛΟΓΙΑ

1,6 εκατ. /έτος θάνατοι παγκοσμίως

Ευρώπη 2017

25% θανάτων από CA άνδρες

15% θανάτων από CA γυναίκες

NSCLC 80-90%

↑ αδενο ↓ πλακώδους

Παράγοντες κινδύνου

Risk factors	*Relative risk*
Tobacco use or exposure	
Current smoking	20
Former smoking	9
Asbestos	3
Radon	3
Other exposures	—
Air pollution	
Arsenic	
Beryllium	
Beta-carotene ingestion	
Chromium	
Nickel	
Soot	

Risk factors	*Relative risk*
Comorbidities	
Human immunodeficiency	2 to 11
pulmonary disease	
Tuberculosis	—
Other	
History of chest radiotherapy	5.9
History of chemotherapy	4.2
Family history of lung cancer	2
Older age	—

19% Μη καπνιστές άνδρες
9% Μη καπνίστριες γυναίκες

Σημειολογία

10% ασυμπτωματικοί
Αύξηση λόγω screening
Αύξηση CTs

Νέο σύμπτωμα
Αλλαγή χαρακτήρα - έντασης

Ενδοθωρακική επέκταση

Sign/symptom of intrathoracic spread	*Clinical context*
Decreased breath sounds and dyspnea	Malignant pleural effusion
Decreased heart sounds and enlarged cardiac silhouette	Malignant pericardial effusion
Dysphagia	Esophageal invasion
Elevated hemidiaphragm	Phrenic nerve paralysis
Facial swelling, plethora, and upper extremity edema	Superior vena cava syndrome
Hoarseness, weak cough	Recurrent laryngeal nerve palsy
Pleuritic chest pain	Chest wall invasion
Ptosis, miosis, facial anhidrosis	Horner syndrome (sympathetic chain compression)
Shoulder pain and muscle wasting along the C8-T3 nerve root	Pancoast tumor (superior sulcus tumor)

Μεταστατική νόσος

Site	*Sign or symptom*	*Frequency (%)*
Any site	Any sign or symptom	33
Liver	Weakness, weight loss, anorexia, hepatomegaly	Up to 60
Bone	Pain, fracture, elevated alkaline phosphatase	Up to 25
Lymphatics	Lymphadenopathy	15 to 20
Brain	Headaches, seizures, nausea and vomiting, mental status changes	Up to 10
Adrenals	Adrenal insufficiency	Rare
Skin	Subcutaneous nodules	Rare

Παρανεοπλασματικά σύνδρομα

Syndrome	*Frequency (%)*	*Comments*
Systemic (anorexia, cachexia, weight loss, fatigue, fever)	0 to 68	May be readily apparent and striking
Digital clubbing	29	More common with non–small cell lung cancer
Hypercalcemia	10 to 20	Ectopic production of parathyroid hormone–related peptide; may be life-threatening
Hyponatremia	1 to 5	Syndrome of inappropriate antidiuretic hormone or ectopic production of atrial natriuretic peptide
Paraneoplastic encephalitis	0.2	Mental status changes
Cushing syndrome	Rare	Ectopic production of adrenocorticotropic hormone
Hypertrophic osteoarthropathy	Rare	Triad of clubbing, arthralgias, and ossifying periostitis
Muscular weakness	Rare	Lambert-Eaton myasthenic syndrome

Ακτινολογία

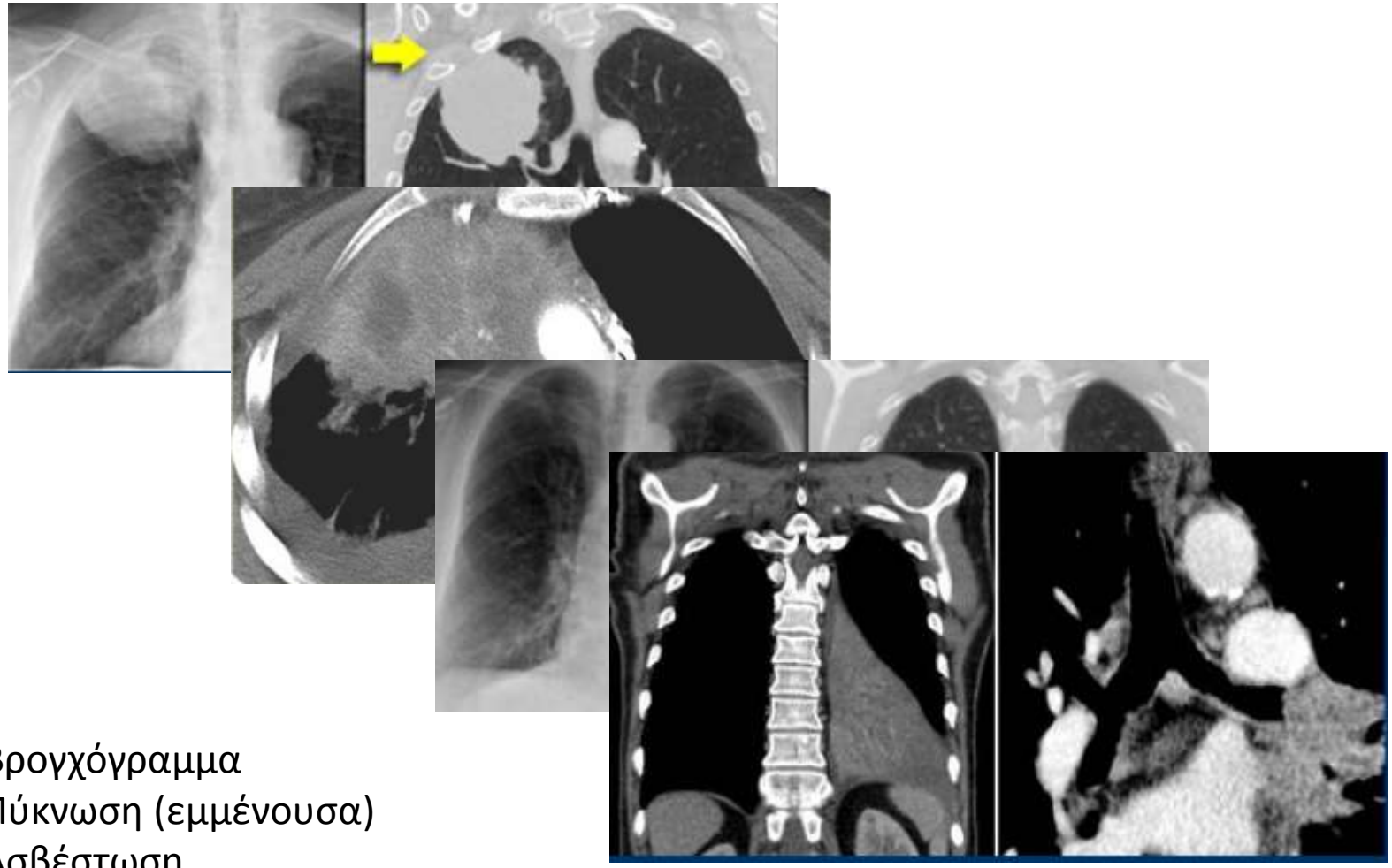

Βρογχόγραμμα
Πύκνωση (εμμένουσα)
Ασβέστωση
Κοιλότητα (έκκεντρη, παχιά τοιχώματα)

ΔΙΑΓΝΩΣΗ - ΣΤΑΔΙΟΠΟΙΗΣΗ

Σταδιοποίηση

Prefix	Name	Definition
c	Clinical	Before initiation of any treatment, using any and all information available (eg, including mediastinoscopy)
p	Pathologic	After resection, made on the basis of pathologic assessment
y	Restaging	After part or all of the treatment has been given
r	Recurrence	Stage at time of a recurrence
a	Autopsy	Stage as determined by autopsy

TNM

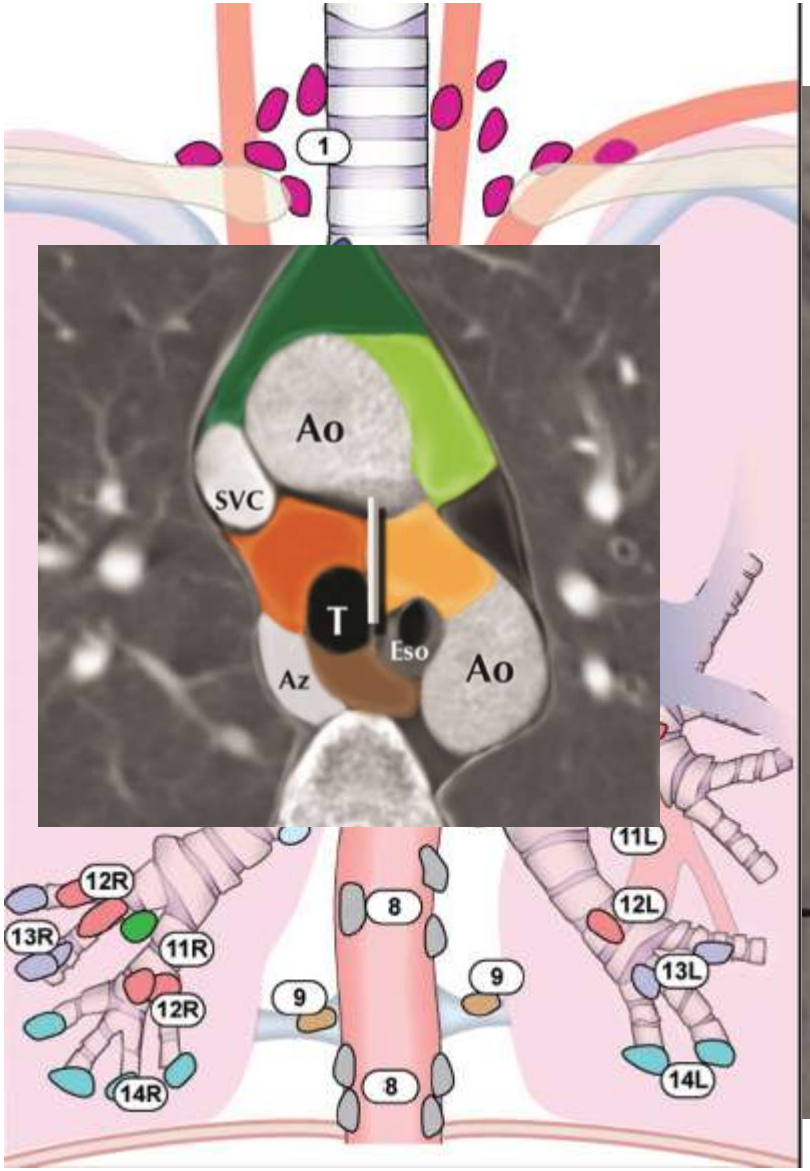
1
Ao
SVC
T
Eso
Az
Ao
12R
13R
11R
12R
14R
8
9
9
8
11L
12L
13L
14L

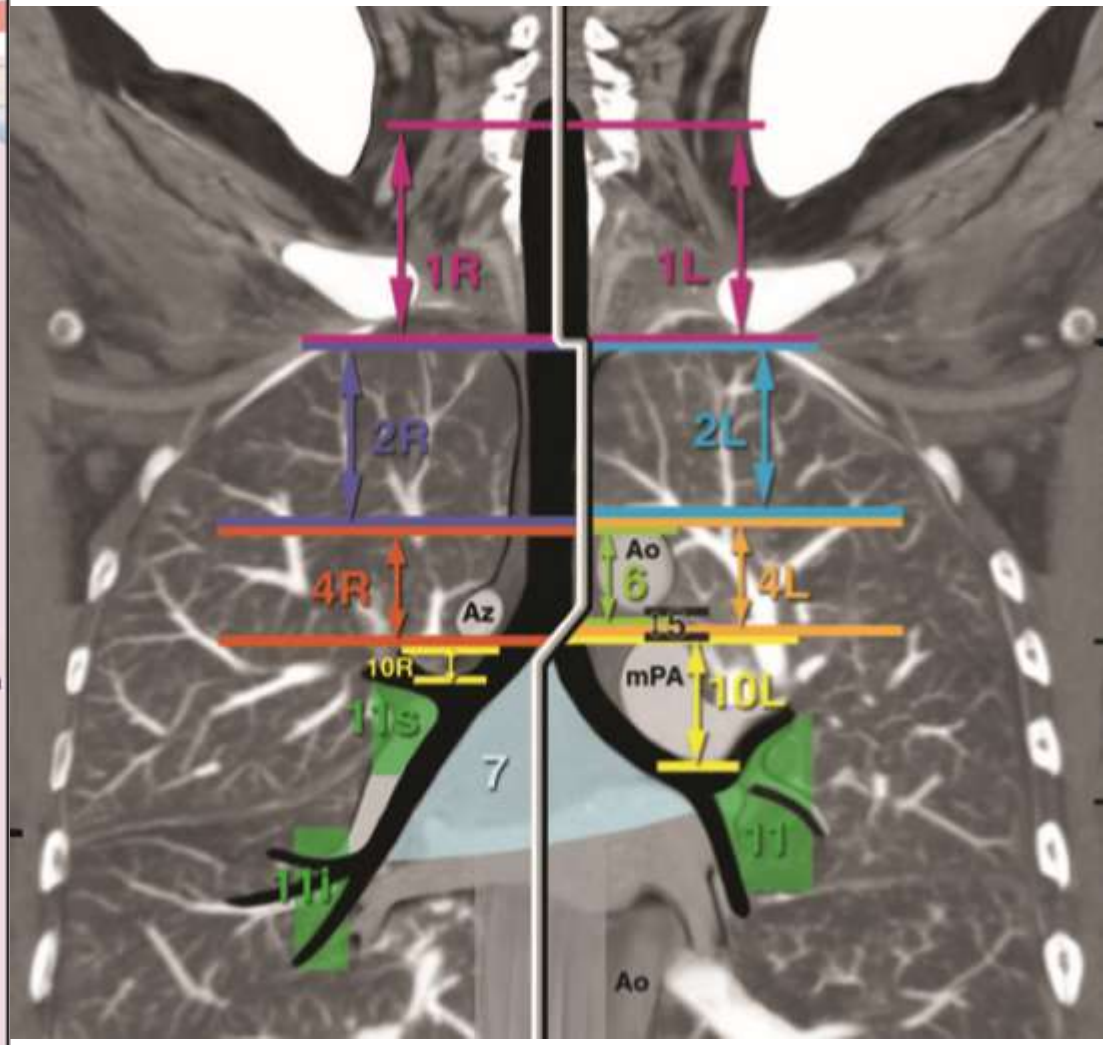
1R
1L
2R
2L
4R
Az
10R
Ao
6
4L
mPA
10L
7
Ao

International Association for the Study of Lung Cancer (IASLC) Lymph Node Map: Radiologic Review with CT Illustration[1]

Ahmed H. El-Sherief, MD
Charles T. Lau, MD
Carol C. Wu, MD
Richard L. Drake, PhD
Gerald F. Abbott, MD
Thomas W. Rice, MD

Abbreviations: IASLC = International Association for the Study of Lung Cancer, SVC = superior vena cava, TNM = tumor, node, metastasis

RadioGraphics 2014; 34:1680–1691

Accurate clinical or pretreatment stage classification of lung cancer leads to optimal treatment outcomes and improved prognostication. Such classification requires an accurate assessment of the clinical extent of regional lymph node metastasis. Consistent and reproducible regional lymph node designations facilitate reliable assessment of the clinical extent of regional lymph node metastasis. Regional lymph node maps, such as the Naruke lymph node map and the Mountain-Dresler modification of the American Thoracic Society lymph node map, were proposed for this purpose in the past. The most recent regional lymph node map to be published is the International Association for the

IASLC INTERNATIONAL ASSOCIATION FOR THE STUDY OF LUNG CANCER

Conquering Thoracic Cancers Worldwide

SECOND EDITION

Staging Manual in Thoracic Oncology

Executive Editor
Ramón Rami-Porta, MD

TNM

T1

Tumor size ≤3cm

- Tumor ≤1cm => T1a
- Tumor >1cm but ≤2cm =>T1b
- Tumor >2cm but ≤3cm => T1c

T1a(mi) is pathology proven 'minimally invasive', irrespective of size.

T1a(ss) is a **s**uperficial **s**preading tumor in the central airways, irrespective of location.

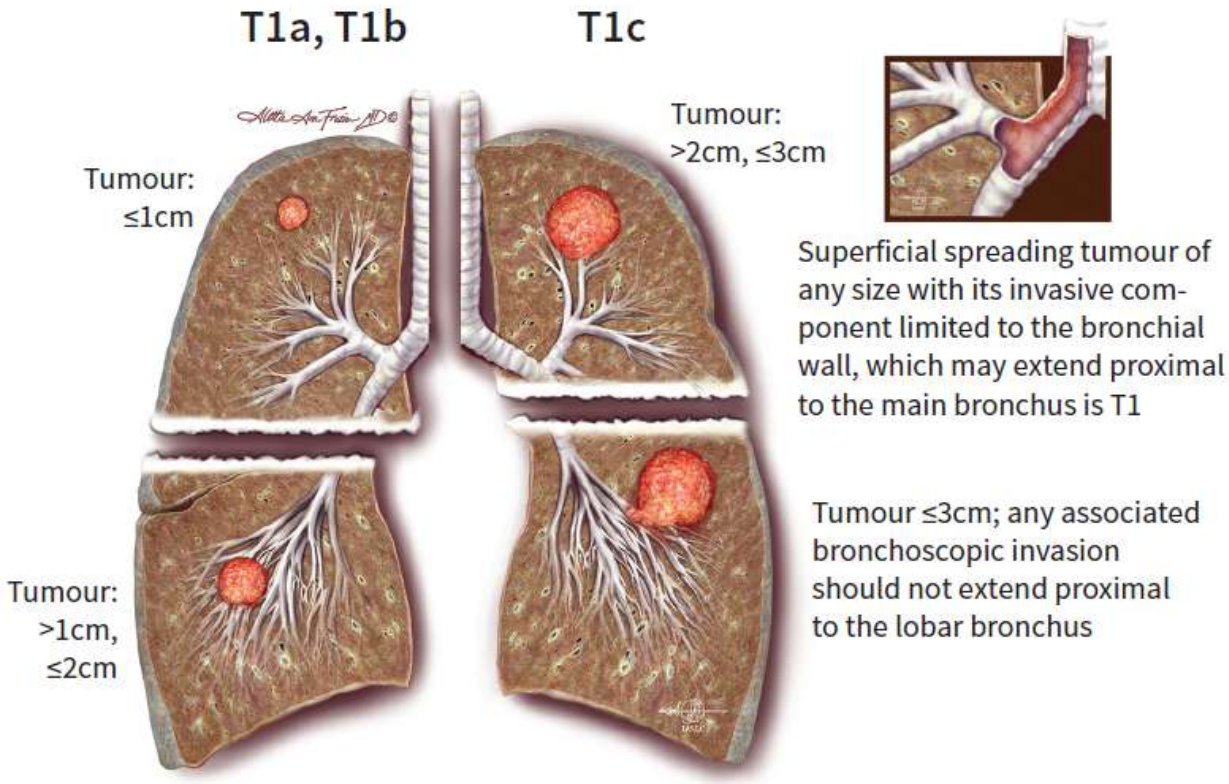

TNM

T2

- Tumor size >3cm to ≤5cm or
- Tumor of any size that
  - invades the visceral pleura
  - involves main bronchus, irrespective of distance to the carina
  - shows an atelectasis or obstructive pneumonitis

T2a= >3 to 4cm
T2b= >4 to 5cm

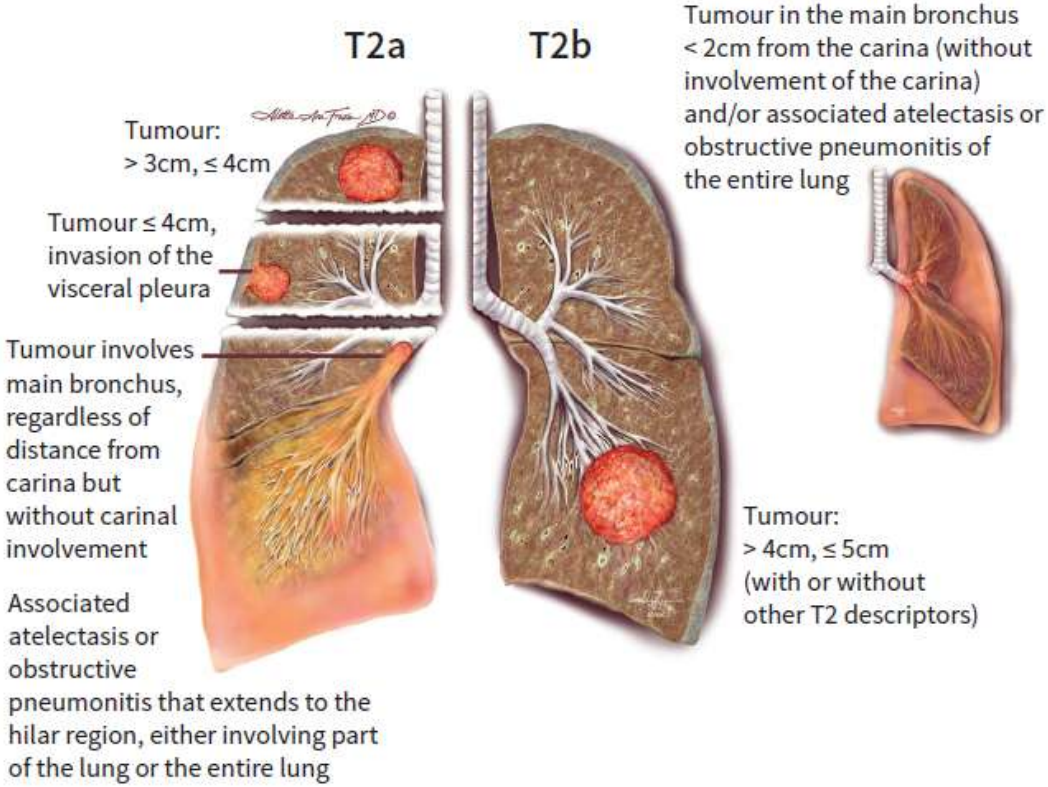

Note: if the tumour is associated with atelectasis or pneumonitis, it is T2a if lesion ≤ 4cm or if tumour size cannot be measured; it is T2b if lesion > 4cm, ≤ 5cm.

TNM

T3

- Tumor size >5cm to 7cm or
- Pancoast that involves thoracic nerve roots T1 and T2 only.
- Tumor of any size that
  - invades the chest wall
  - invades the pericardium
  - invades the phrenic nerve
  - shows one or more satellite nodules in the same lung lobe

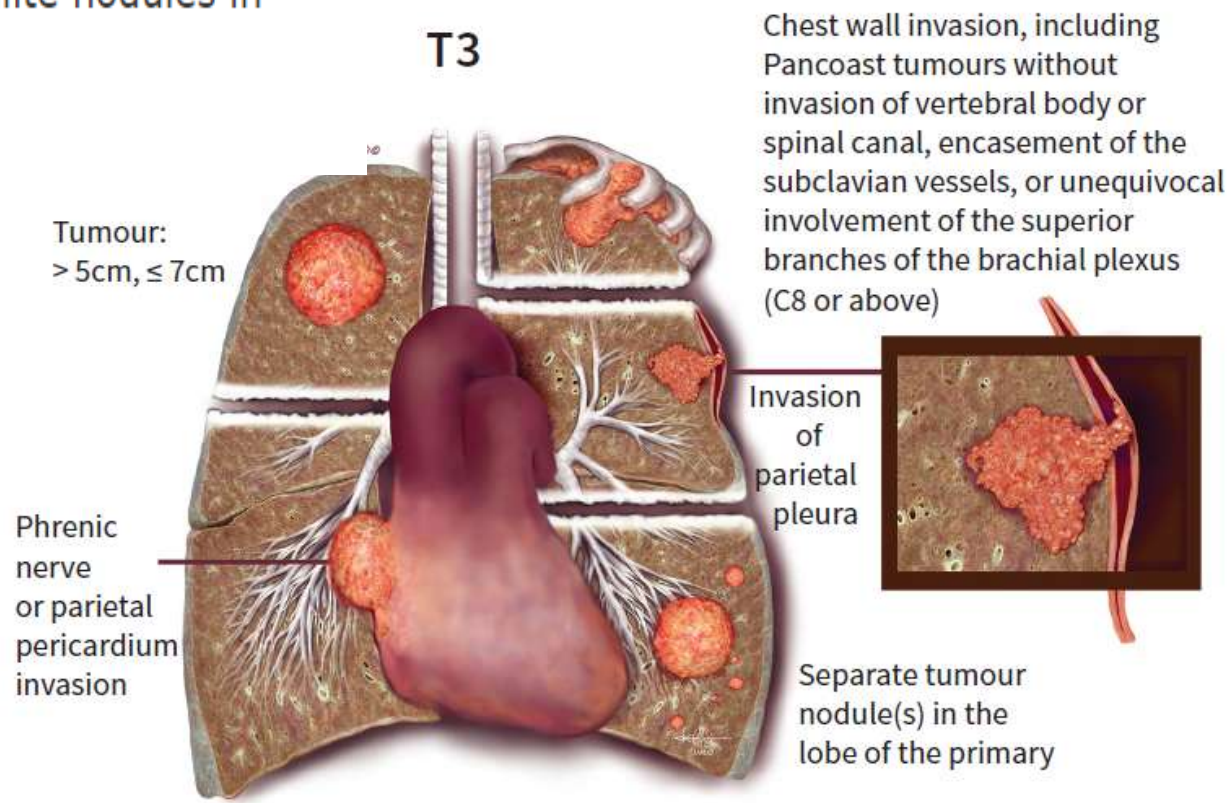

TNM

T4

- Tumor size >7cm or
- Pancoast tumor that involves C8 or higher nerve roots, brachial plexus, subclavian vessels or spine
- Tumor of any size that
  - invades mediastinal fat or mediastinal structures
  - invades the diaphragm
  - involves the carina
  - shows one or more satellite nodules in another lobe on the ipsilateral side

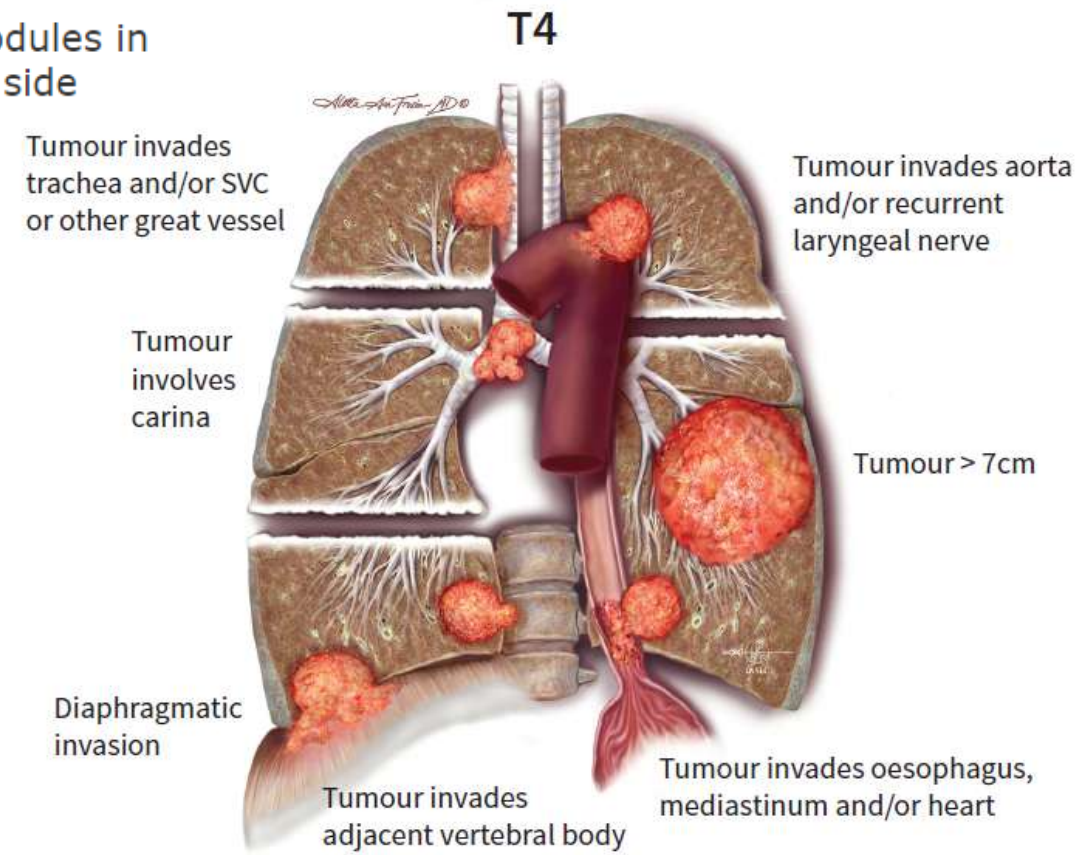

TNM

T4

Pancoast tumours with invasion of one or more of the following structures:
- vertebral body or spinal canal
- brachial plexus (C8 or above)
- subclavian vessels

Tumour accompanied by ipsilateral, separate tumour nodules, different lobe

	TNM 7th EDITION	TNM 8th EDITION
T	-	Tis
	-	Tmi
	-	Tss
	T1a (≤2 cm) →	T1a (≤1 cm)
	T1b (>2 -3 cm)	T1b (>1-2cm)
		T1c (>2-3cm)
	T2a (>3-5 cm) →	T2a (>3cm but ≤4cm)
	T2b (>5-7 cm)	T2b (>4cm but ≤5cm)
	T3 (>7 cm) →	T4
	T3 - atelectasis/pneumonitis involving whole lung)	T2 atelectasis/pneumonitis irrespective of involving lobe or whole lung
	T3 tumor involving the main bronchus <2cm distance to carina →	T2 -tumor involving the main bronchus irrespective of distance to carina
	T3 -invasion of the diaphragm →	T4 (invasion of the diaphragm)
N	No changes	
M	M1b - distant metastasis →	M1b - single extrathoracic metastasis
		M1c - multiple extrathoracic metastases

New T categories

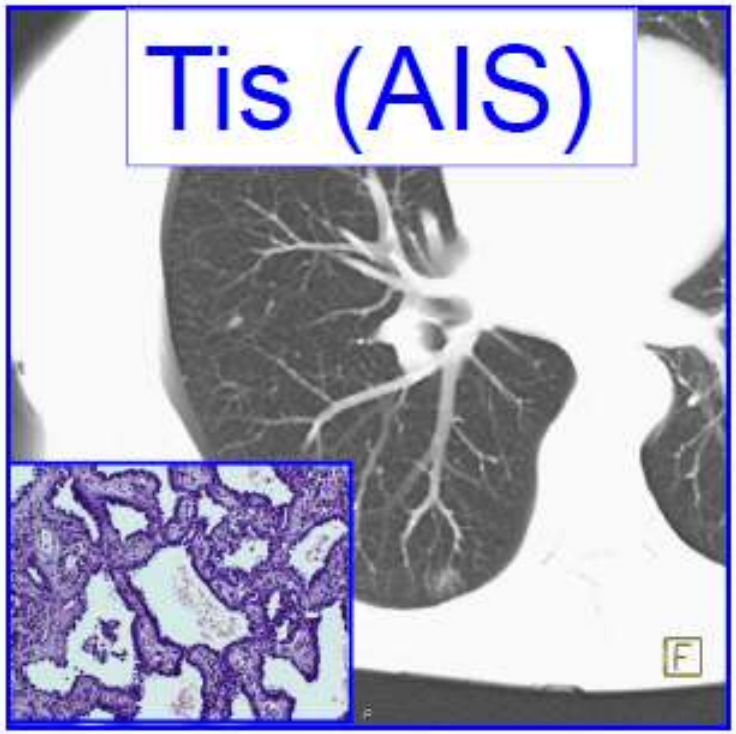

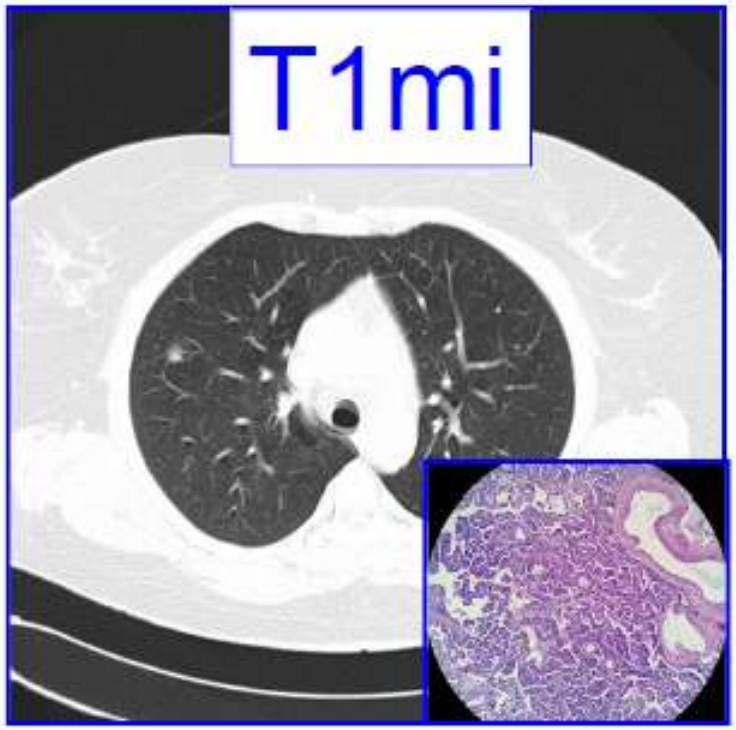

Travis W et al. J Thorac Oncol 2016; 11: 1204-1223.

T1mi

[c] Solitary adenocarcinoma (not more than 3 cm in greatest dimension), with a predominantly lepidic pattern and not more than 5 mm invasion in greatest dimension in any one focus.

The T component

Size measurement in part-solid non-mucinous ADK

Clinical size:
size of
solid component

Pathologic size:
size of
invasive component

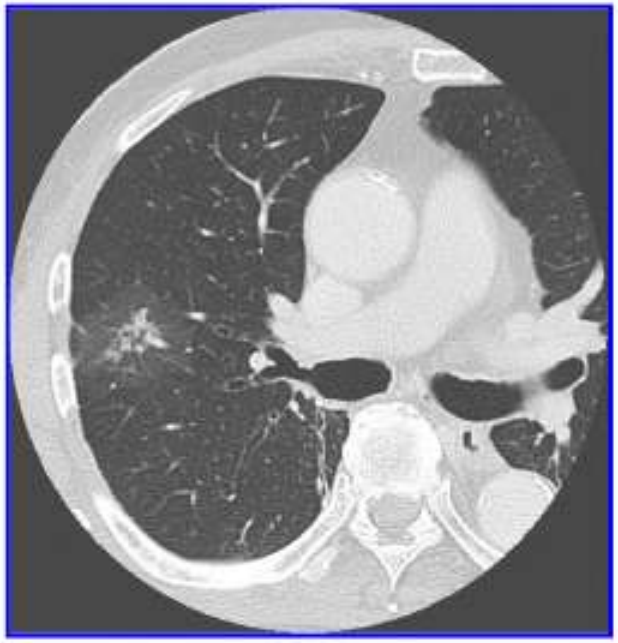

Courtesy of Dr. H. Asamura

Travis W et al. J Thorac Oncol 2016; 11: 1204-1223.

The T component

Measurement of tumour size

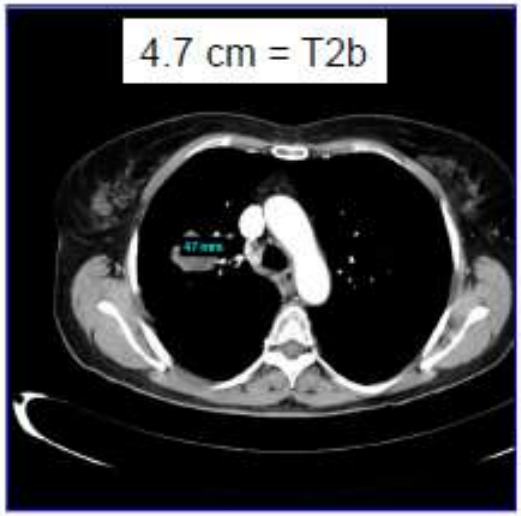

IASLC recommendation for the measurement of tumour size:

Lung window

Travis W et al. J Thorac Oncol 2016; 11: 1204-1223.

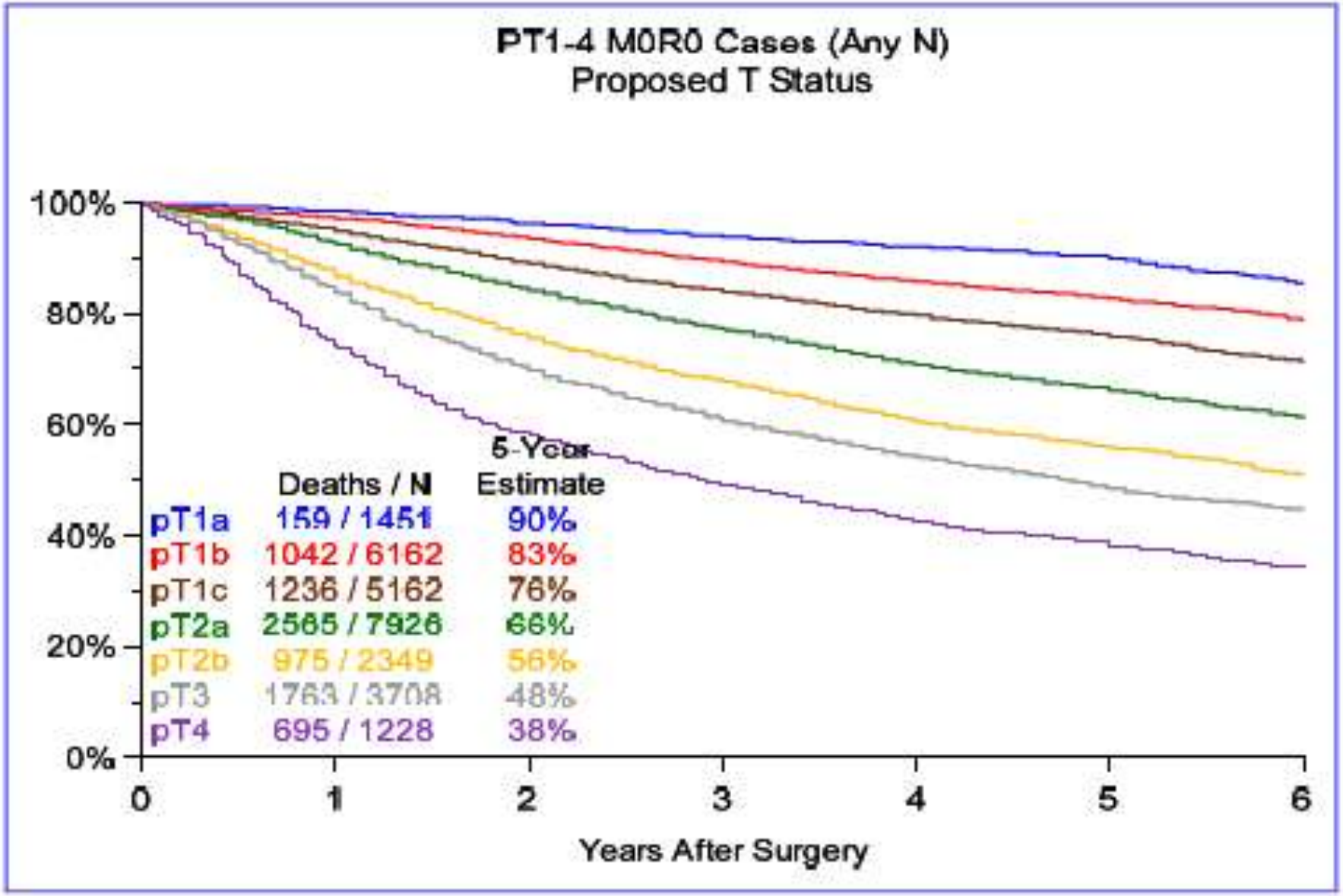
PT1-4 M0R0 Cases (Any N)
Proposed T Status
100%
80%
60%
40%
20%
0%
0
1
2
3
4
5
6
Years After Surgery
Deaths / N
5-Year Estimate
pT1a 159 / 1451 90%
pT1b 1042 / 6162 83%
pT1c 1236 / 5162 76%
pT2a 2565 / 7926 66%
pT2b 975 / 2349 56%
pT3 1763 / 3708 48%
pT4 695 / 1228 38%

TNM

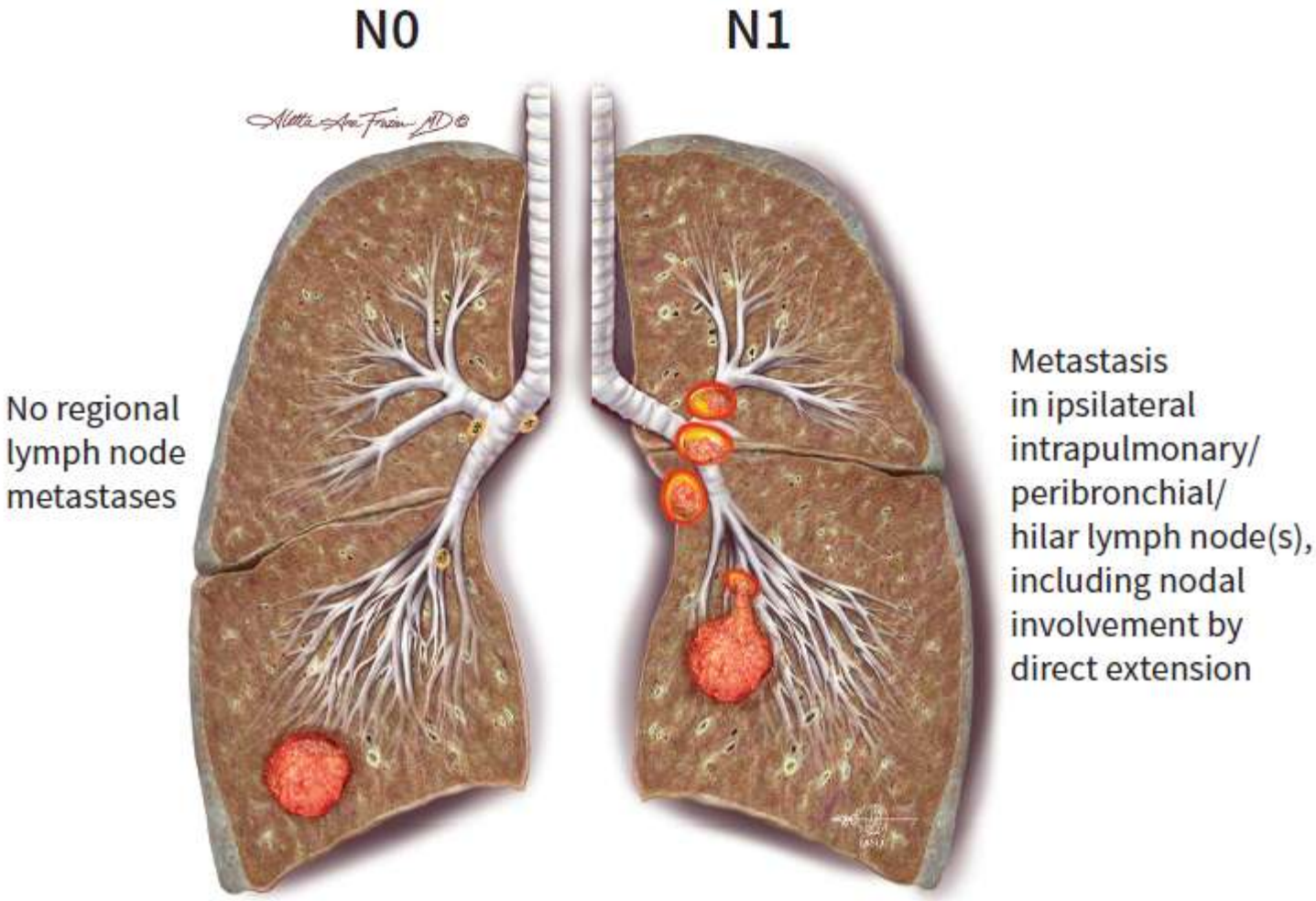
N0
N1
No regional lymph node metastases
Metastasis in ipsilateral intrapulmonary/ peribronchial/ hilar lymph node(s), including nodal involvement by direct extension

TNM

N2

Metastasis in ipsilateral mediastinal and/or subcarinal lymph node(s), including “skip” metastasis without N1 involvement

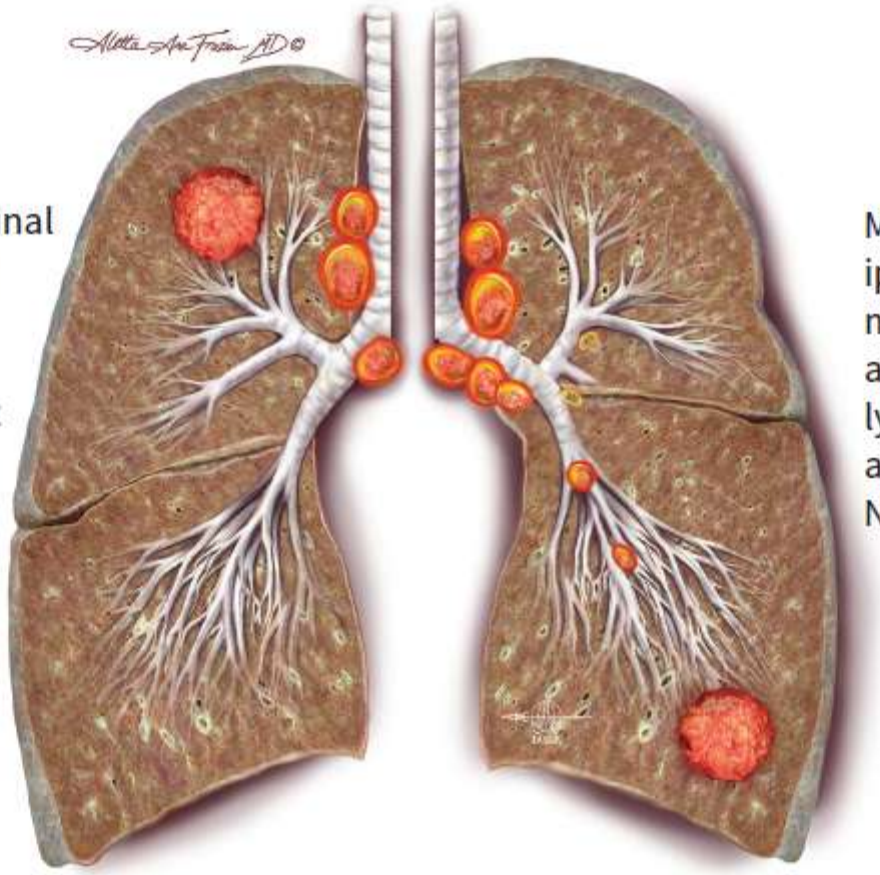

Metastasis in ipsilateral mediastinal and/or subcarinal lymph node(s) associated with N1 disease

TNM

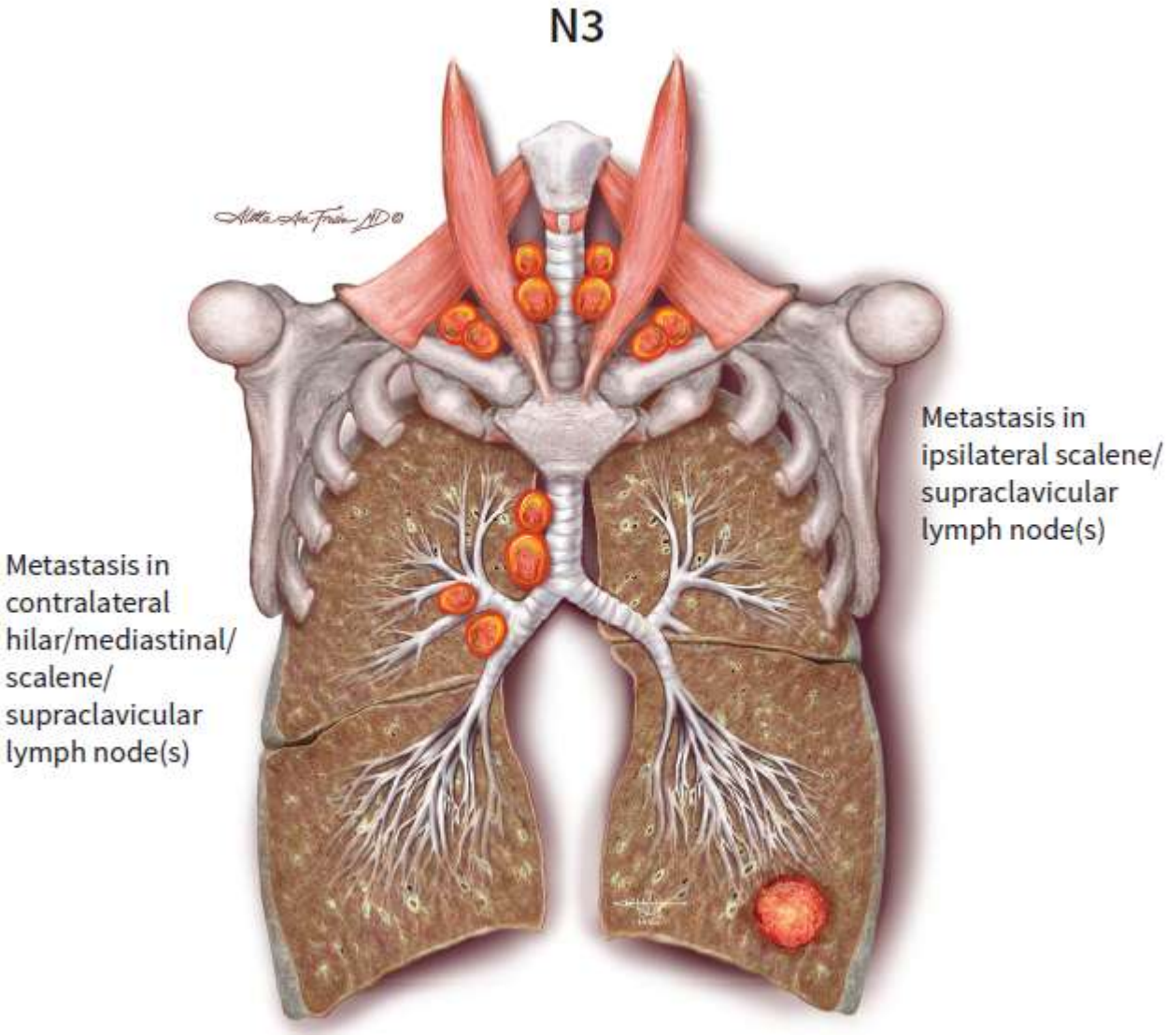
N3
Metastasis in ipsilateral scalene/ supraclavicular lymph node(s)
Metastasis in contralateral hilar/mediastinal/ scalene/ supraclavicular lymph node(s)

Quantification of nodal disease

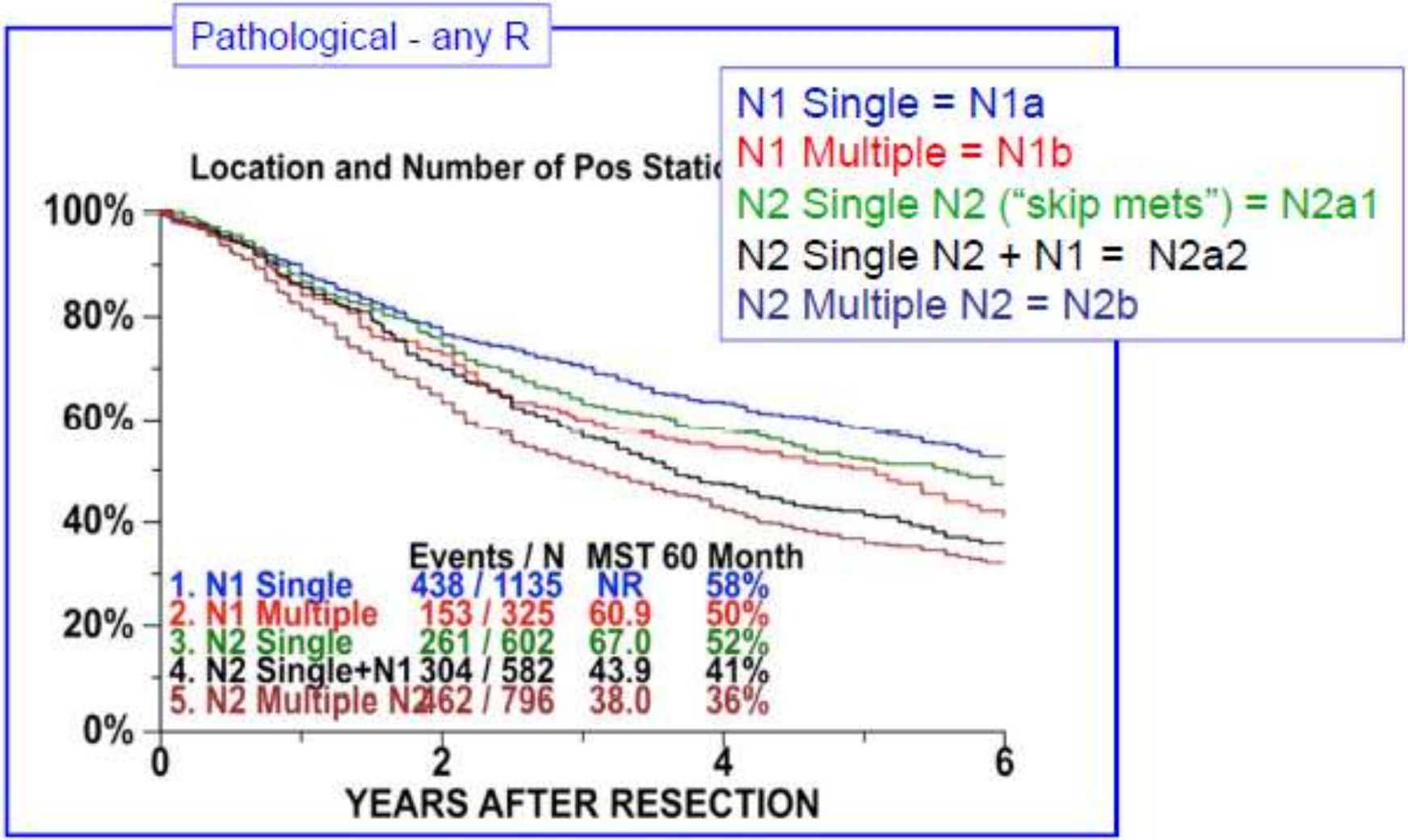

Asamura H et al. J Thorac Oncol 2015; 10: 1675-84.

TNM

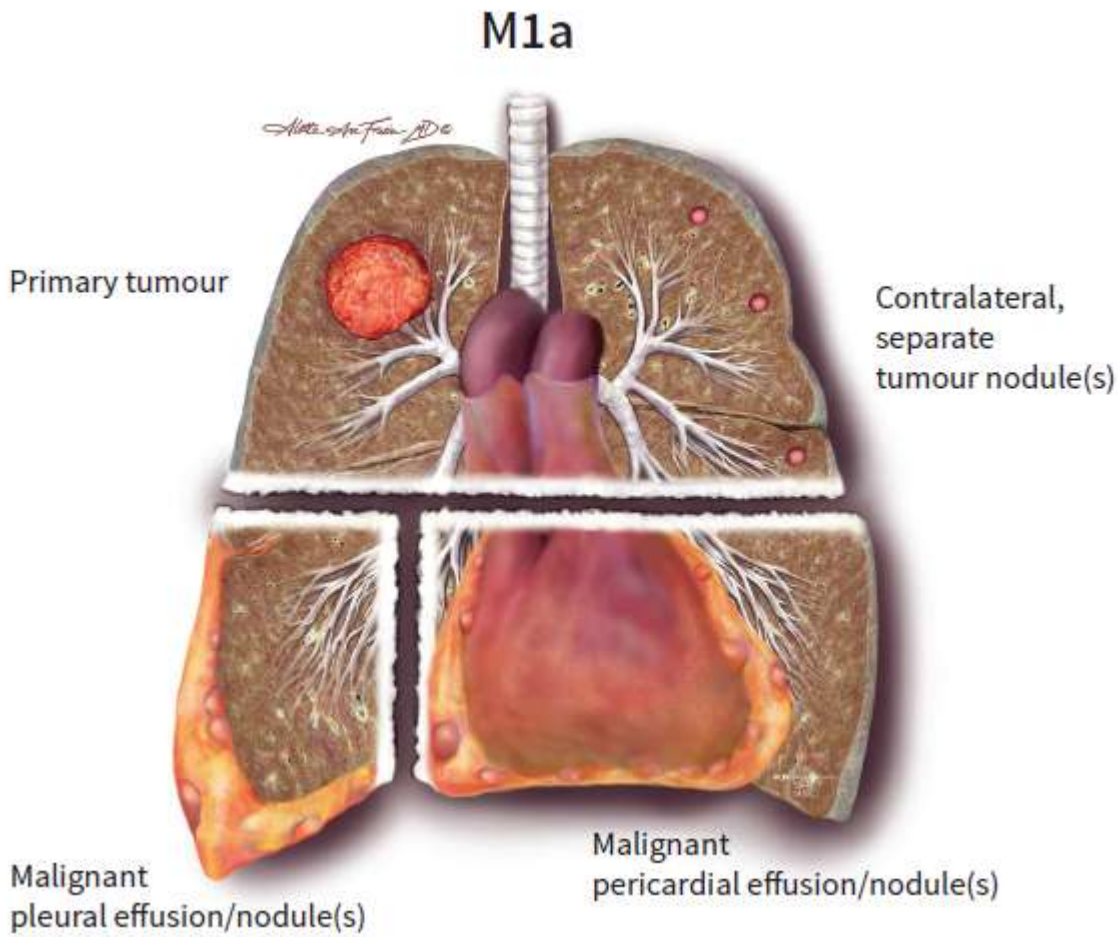
M1a
Primary tumour
Contralateral, separate tumour nodule(s)
Malignant pleural effusion/nodule(s)
Malignant pericardial effusion/nodule(s)

TNM

M1b

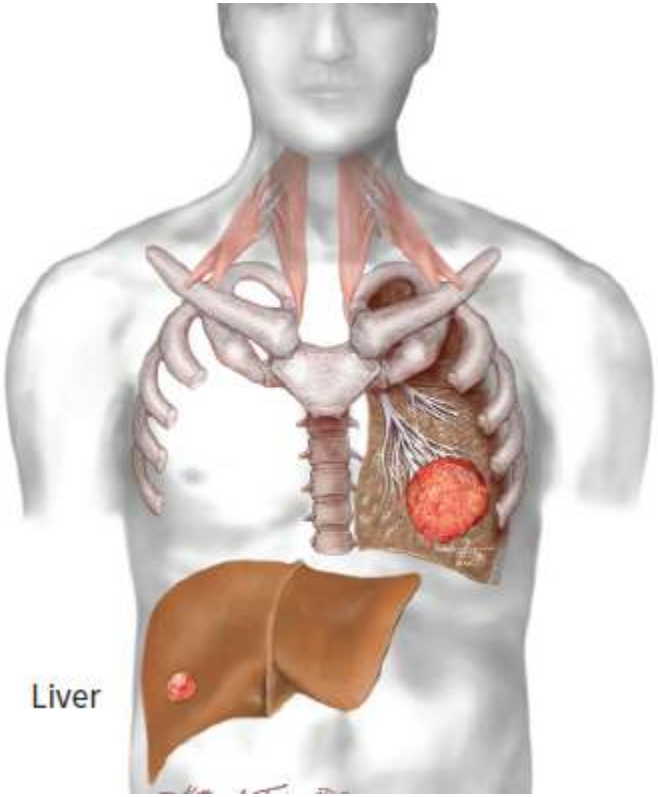
Single extrathoracic metastasis
Liver

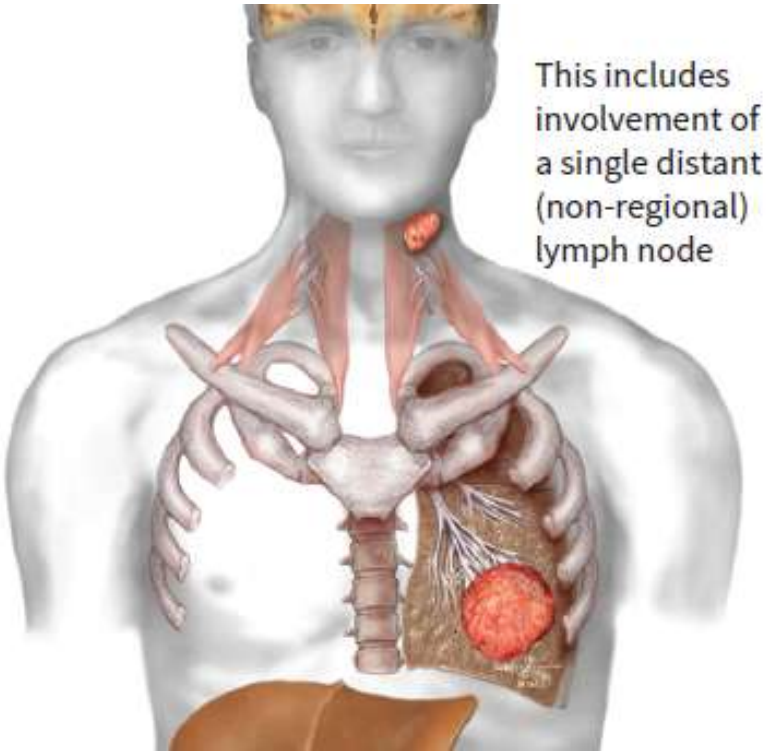
This includes involvement of a single distant (non-regional) lymph node

TNM

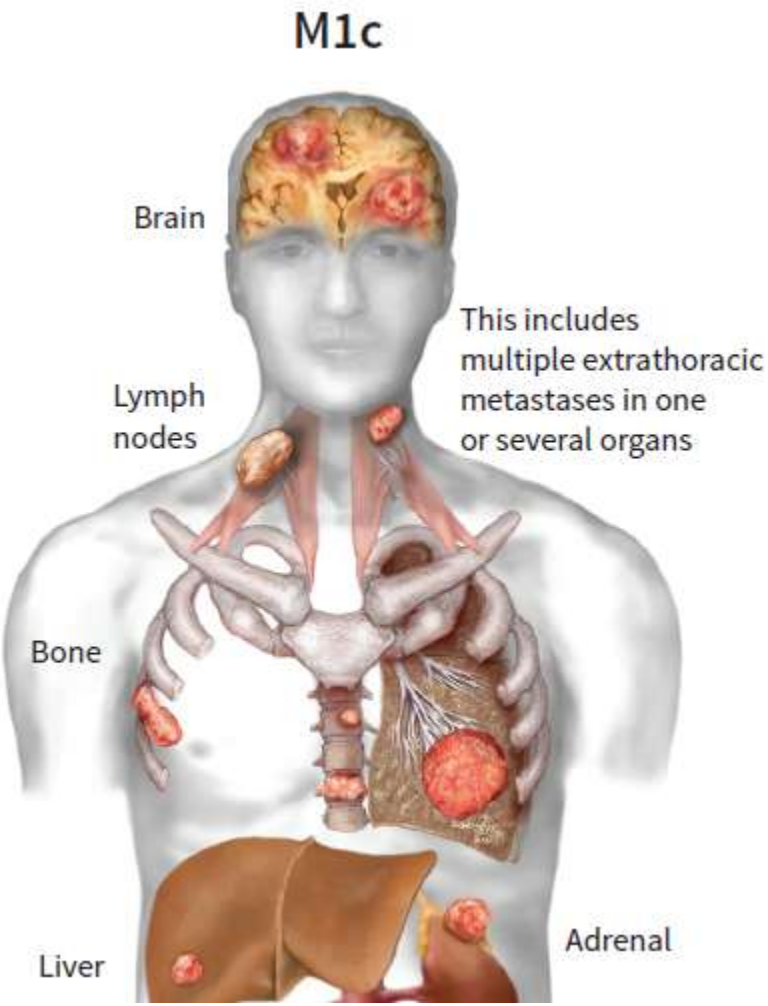
M1c
Brain
This includes multiple extrathoracic metastases in one or several organs
Lymph nodes
Bone
Liver
Adrenal

The M component: M1b

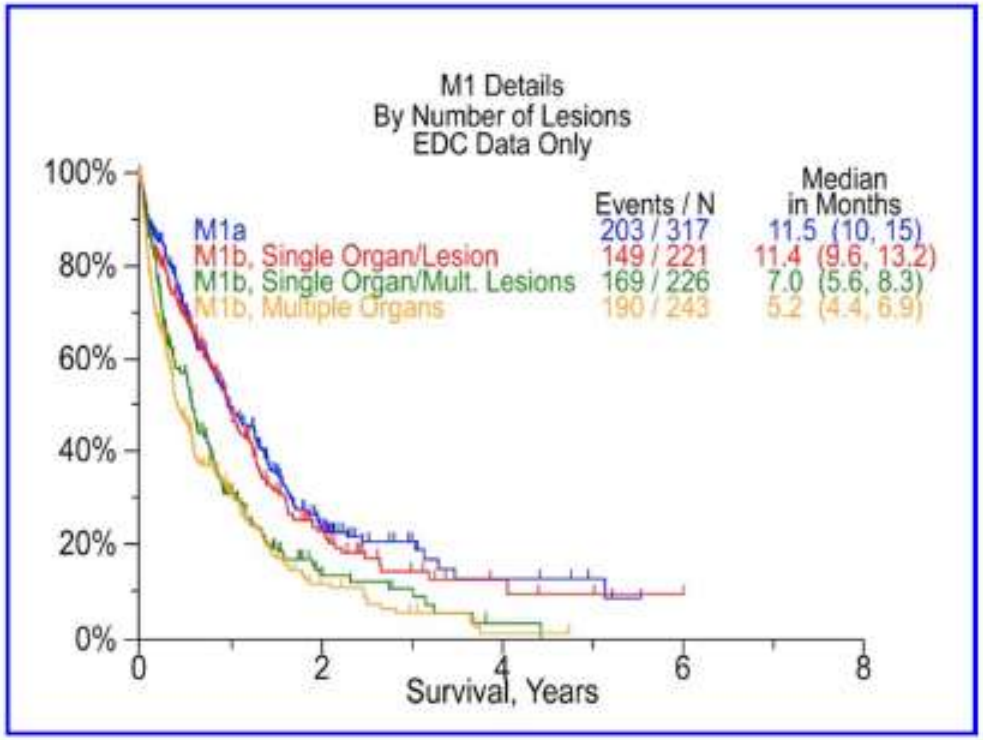

Eberhardt W et al. J Thorac Oncol 2015; 10: 1515-1522.

M1a

M1b

M1c

M1c

Stage groupings

	N0	N1	N2	N3	M1a any N	M1b any N	M1c any N
T1a	IA1	IIB	IIIA	IIIB	IVA	IVA	IVB
T1b	IA2	IIB	IIIA	IIIB	IVA	IVA	IVB
T1c	IA3	IIB	IIIA	IIIB	IVA	IVA	IVB
T2a	IB	IIB	IIIA	IIIB	IVA	IVA	IVB
T2b	IIA	IIB	IIIA	IIIB	IVA	IVA	IVB
T3	IIB	IIIA	IIIB	IIIC	IVA	IVA	IVB
T4	IIIA	IIIA	IIIB	IIIC	IVA	IVA	IVB

Goldstraw P et al. J Thorac Oncol 2016; 11: 39-51.

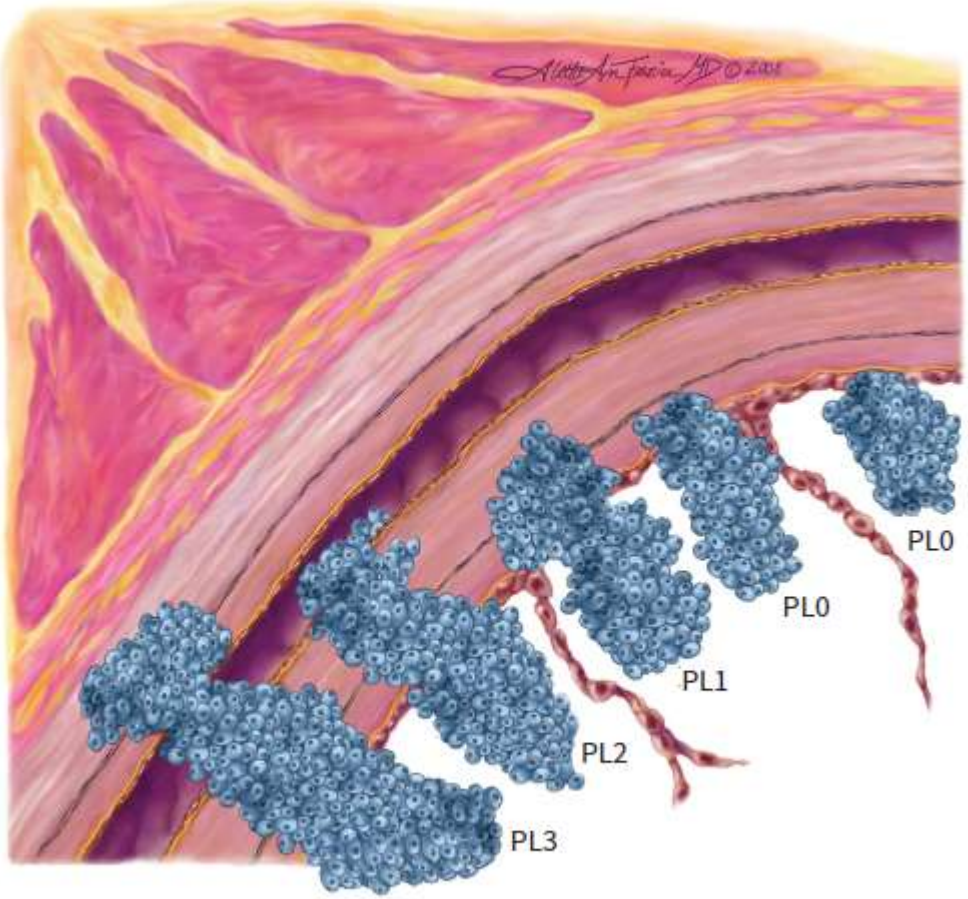

Figure 7.1. Visceral pleural invasion. Copyright ©2016 Aletta Ann Frazier, MD.

CLINICAL PRACTICE GUIDELINES

Diagnosis and pathology/molecular biology

Work-up for diagnosis and staging

Parameter	Mandatory	Optional
General	Medical history* Physical examination* Assessing comorbidity Performance status	
Imaging	X-ray thorax CT thorax* PET-CT thorax* MRI brain†	Bone scintigraphy Contrast-enhanced CT brain
Laboratory	Blood cell counts Renal function Liver enzymes Bone parameters	
Cardio-pulmonary function	FVC, FEV_1, DLCO ECG If indicated: CPET	Ejection fraction, CAG
Tissue procurement	Bronchoscopy‡,§ EBUS/EUS mediastinal nodes* CT-guided biopsy	Mediastinoscopy

*Tests needed for clinical staging

†Screening for brain metastases by MRI might be useful in patients considered for curative therapy

‡Depending on site and size of tumour with biopsy/aspiration/brush/washing

§Bronchoscopy is usually sufficient to diagnose NSCLC, though may not allow a detailed sub-classification

ESMO

© 2017 ESMO. All rights reserved. esmo.org/Guidelines/Lung-and-Chest-Tumours/Early-Stage-and-Locally-Advanced-non-metastatic-Non-Small-Cell-Lung-Cancer

TREATMENT OF THORACIC DISEASE

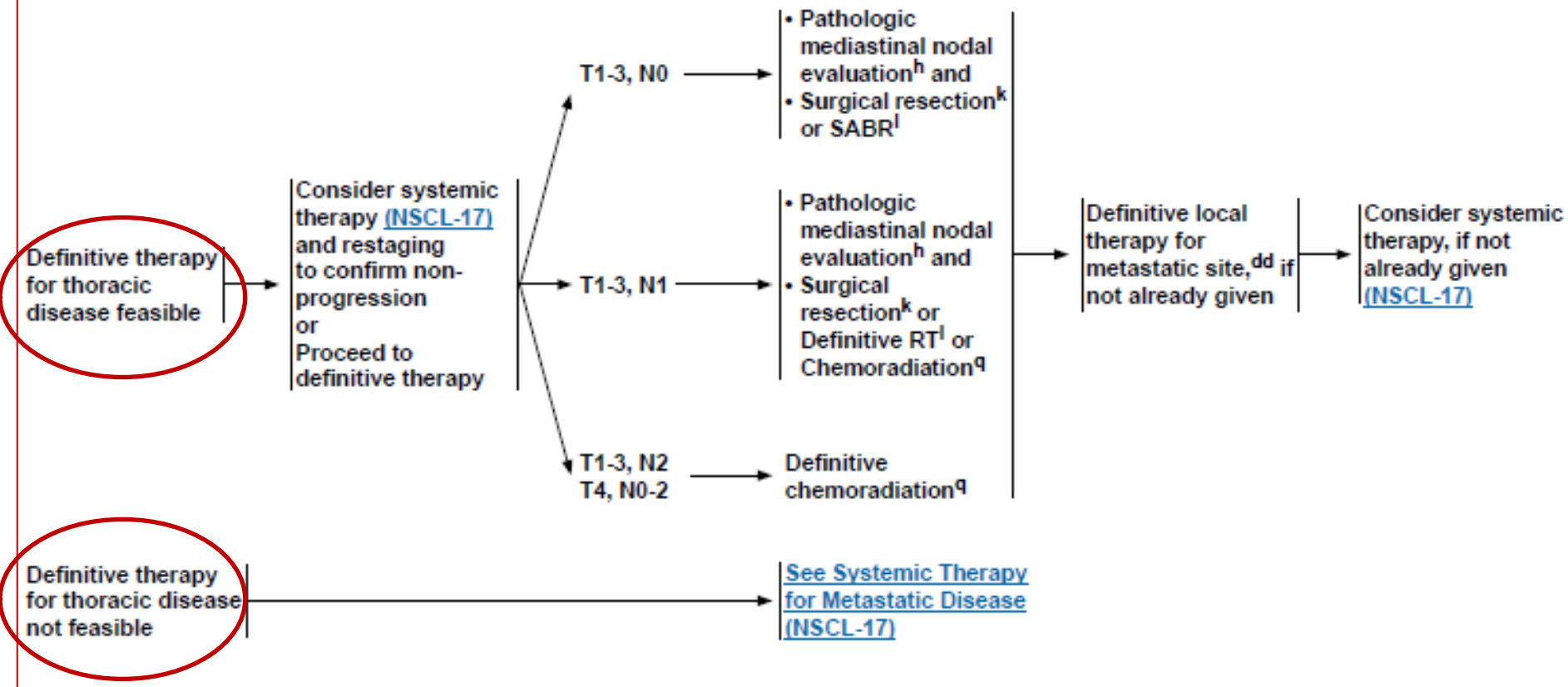

Suspected NSCLC

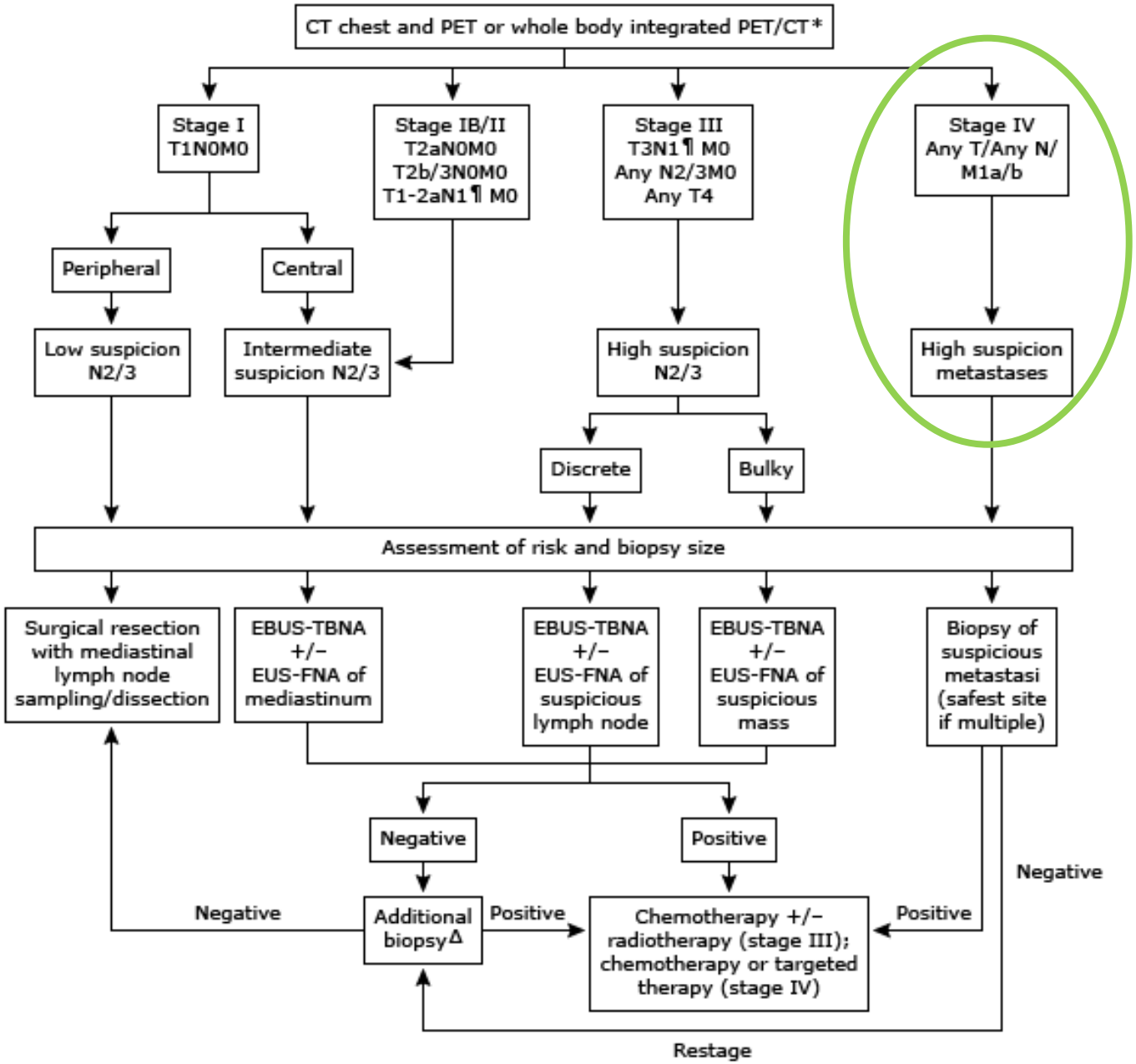

Suspected NSCLC

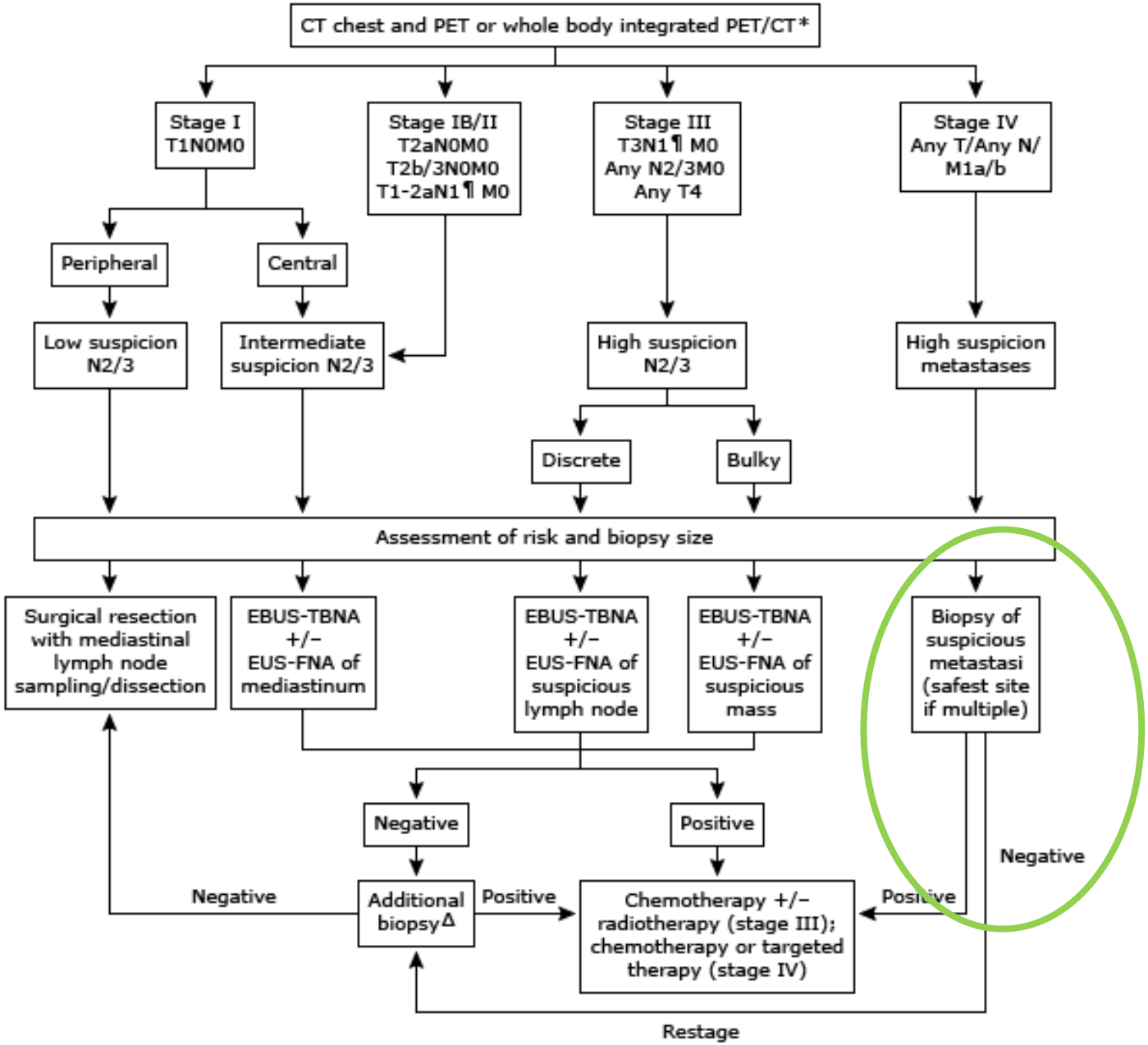

Παρακέντηση
VATS
Θωρακοσκόπηση

CHEST Supplement

DIAGNOSIS AND MANAGEMENT OF LUNG CANCER, 3RD ED: ACCP GUIDELINES

Methods for Staging Non-small Cell Lung Cancer

Diagnosis and Management of Lung Cancer, 3rd ed: American College of Chest Physicians Evidence-Based Clinical Practice Guidelines

Gerard A. Silvestri, MD, FCCP; Anne V. Gonzalez, MD; Michael A. Jantz, MD, FCCP; Mitchell L. Margolis, MD, FCCP; Michael K. Gould, MD, FCCP; Lynn T. Tanoue, MD, FCCP; Loren J. Harris, MD, FCCP; and Frank C. Detterbeck, MD, FCCP

Mediastinal staging in NSCLC	n	Sen (%)	Spe (%)	PPV (%)	NPV (%)
Thorax CT	7368	55	81	58	83
PET-CT	2014	62	90	63	90
PET	4105	80	88	75	91
TBNA	2408	78	100	100	77
Mediastinoscopy	10648	81	100	100	91
EUS-TBNA	2443	89	100	100	86
EBUS-TBNA	2756	89	100	100	91
EBUS+EUS-FNA	811	91	100	100	96

Ενδοβρογχικό υπερηχογράφημα

In patients with high suspicion of N2,3 involvement, either by discrete mediastinal lymph node enlargement or PET uptake (and no distant metastases), a needle technique (EBUS-NA, EUS-NA or combination EBUS/EUS-NA) is recommended over surgical staging as a first test (grade 1B)

- Διακριτοί λεμφαδένες
- > 1cm ή PET (+)
- Όχι “M”

EBUS (επί αρνητικών μεσοθωρακοσκόπηση) +/- EUS

Diagnosis and Management of Lung Cancer: ACCP Guidelines 2013

Ενδοβρογχικό υπερηχογράφημα

In patients with high suspicion of N2,3 involvement, either by discrete mediastinal lymph node enlargement or PET uptake (and no distant metastases), a needle technique (EBUS-NA, EUS-NA or combination EBUS/EUS-NA) is recommended over surgical staging as a first test (grade 1B)

- Διακριτοί λεμφαδένες
- > 1cm ή PET (+)
- Όχι “Μ”

EBUS (επί αρνητικών μεσοθωρακοσκόπηση) +/- EUS

Diagnosis and Management of Lung Cancer: ACCP Guidelines 2013

Ενδοβρογχικό υπερηχογράφημα

In patients with high suspicion of N2,3 involvement, either by discrete mediastinal lymph node enlargement or PET uptake (and no distant metastases), a needle technique (EBUS-NA, EUS-NA or combination EBUS/EUS-NA) is recommended over surgical staging as a first test (grade 1B)

- Διακριτοί λεμφαδένες
- > 1cm ή PET (+)
- Όχι “M”

EBUS (επί αρνητικών μεσοθωρακοσκόπηση) +/- EUS

Diagnosis and Management of Lung Cancer: ACCP Guidelines 2013

Ενδοβρογχικό υπερηχογράφημα

For patients with normal mediastinal nodes but enlarged N1 node or central tumor (ie, medial 1/3 of lung on axial CT cuts)

- Invasive confirmation is recommended (regardless of whether a PET scan finding is positive or negative) 1C
- A needle technique (EBUS-NA, EUS-NA or combined EBUS/EUS-NA) is suggested over surgical staging as a best first method (Grade 2B)

- Φυσιολογικό μεσοθωράκιο
- Διογκωμένοι N1
- Κεντρική βλάβη (έσω 1/3 πνεύμονα)
- Ανεξάρτητα του PET

EBUS (επί αρνητικών μεσοθωρακοσκόπηση) +/- EUS

Diagnosis and Management of Lung Cancer: ACCP Guidelines 2013

Ενδοβρογχικό υπερηχογράφημα

For patients with normal mediastinal nodes but enlarged N1 node or central tumor (ie, medial 1/3 of lung on axial CT cuts)

- Invasive confirmation is recommended (regardless of whether a PET scan finding is positive or negative) 1C
- A needle technique (EBUS-NA, EUS-NA or combined EBUS/EUS-NA) is suggested over surgical staging as a best first method (Grade 2B)

- Φυσιολογικό μεσοθωράκιο
- Διογκωμένοι N1
- Κεντρική βλάβη (έσω 1/3 πνεύμονα)
- Ανεξάρτητα του PET

EBUS (επί αρνητικών μεσοθωρακοσκόπηση) +/- EUS

Diagnosis and Management of Lung Cancer: ACCP Guidelines 2013

Ενδοβρογχικό υπερηχογράφημα

For patients with normal mediastinal nodes but enlarged N1 node or central tumor (ie, medial 1/3 of lung on axial CT cuts)

- Invasive confirmation is recommended (regardless of whether a PET scan finding is positive or negative) 1C
- A needle technique (EBUS-NA, EUS-NA or combined EBUS/EUS-NA) is suggested over surgical staging as a best first method (Grade 2B)

- Φυσιολογικό μεσοθωράκιο
- Διογκωμένοι N1
- Κεντρική βλάβη (έσω 1/3 πνεύμονα)
- Ανεξάρτητα του PET

EBUS (επί αρνητικών μεσοθωρακοσκόπηση) +/- EUS

Diagnosis and Management of Lung Cancer: ACCP Guidelines 2013

GUI

Combined endobronchial and esophageal endosonography for the diagnosis and staging of lung cancer: European Society of Gastrointestinal Endoscopy (ESGE) Guideline, in cooperation with the European Respiratory Society (ERS) and the European Society of Thoracic Surgeons (ESTS)

Peter Vilmann[1,*], Paul Frost Clementsen[2,11], Sara Colella[2], Mette Siemsen[3], Paul De Leyn[4], Jean-Marc Dumonceau[5], Felix J. Herth[6], Alberto Larghi[7], Enrique Vazquez-Sequeiros[8], Cesare Hassan[7], Laurence Crombag[9], Daniël A. Korevaar[10], Lars Konge[11] and Jouke T. Annema[9]

3 In patients with suspected or proven <3 cm peripheral NSCLC with normal mediastinal and hilar nodes at CT and/or PET, we suggest initiation of therapy without further mediastinal staging (Recommendation grade C).

Suspected NSCLC

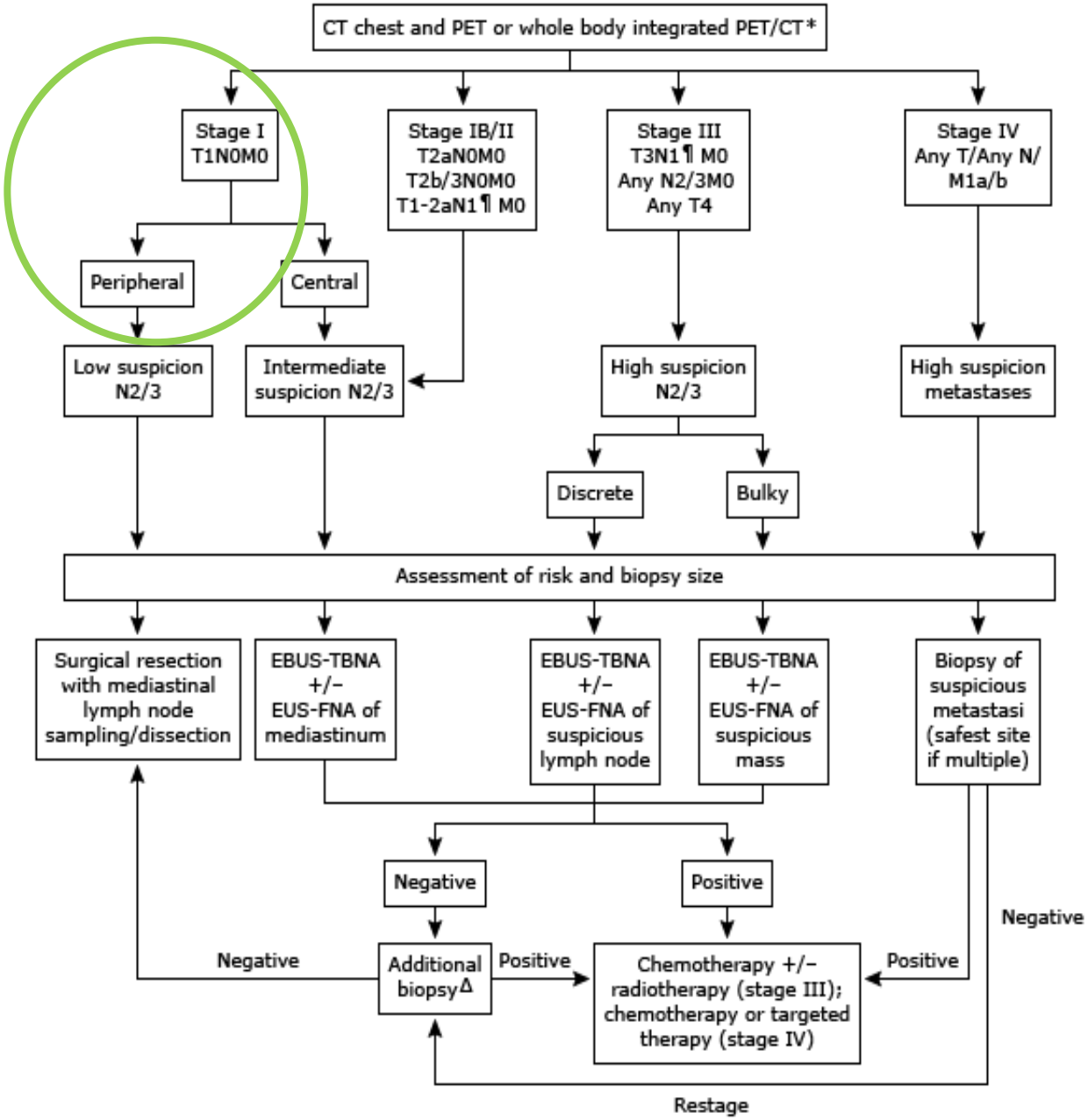

Suspected NSCLC

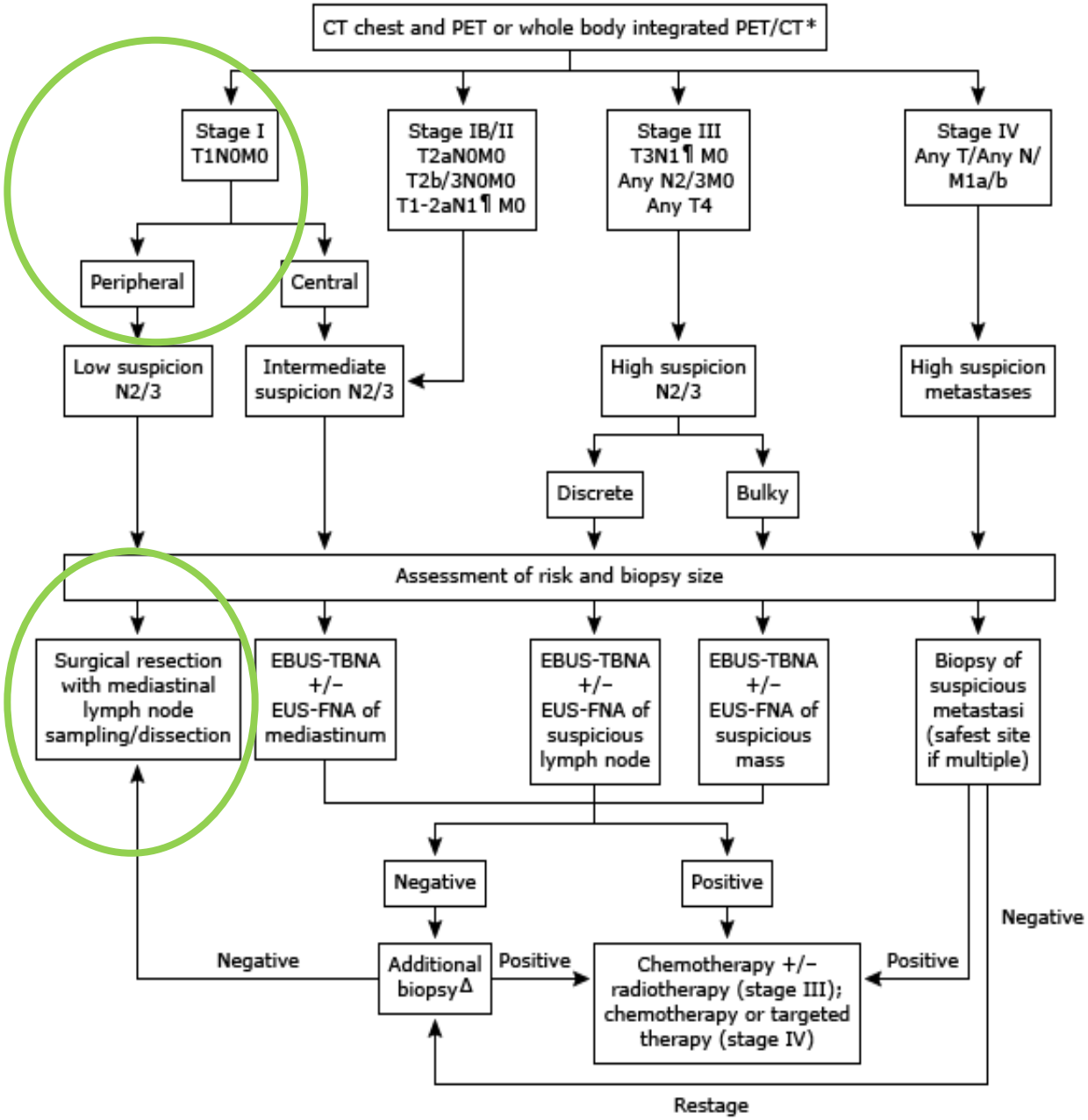

Suspected NSCLC

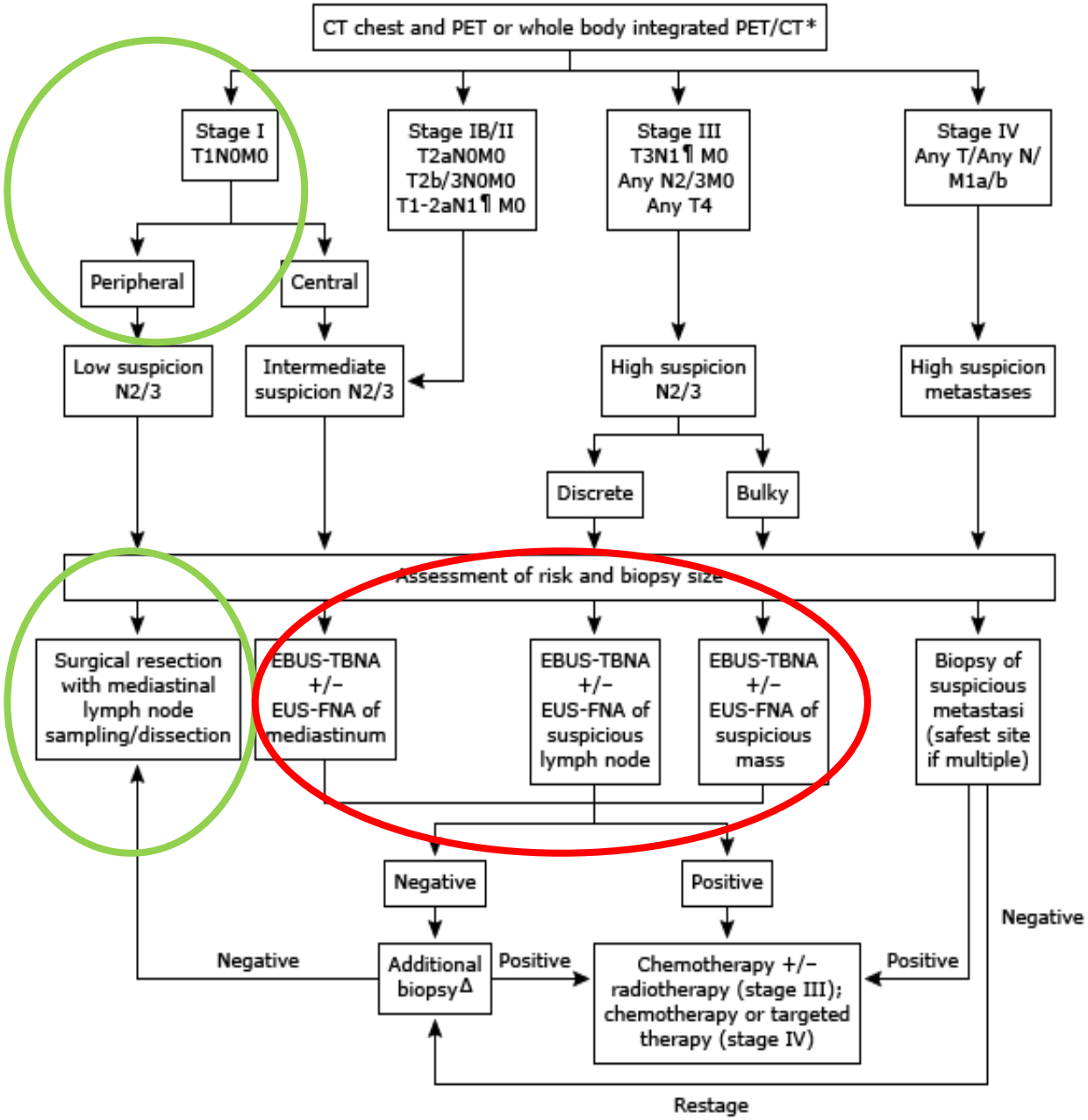

ΧΑΣΑΜΕ ΤΟ ΜΕΣΟΘΩΡΑΚΙΟ
Θ/Χ
Θ/
Θ/Χ
Θ/Χ
148
33

Suspected NSCLC

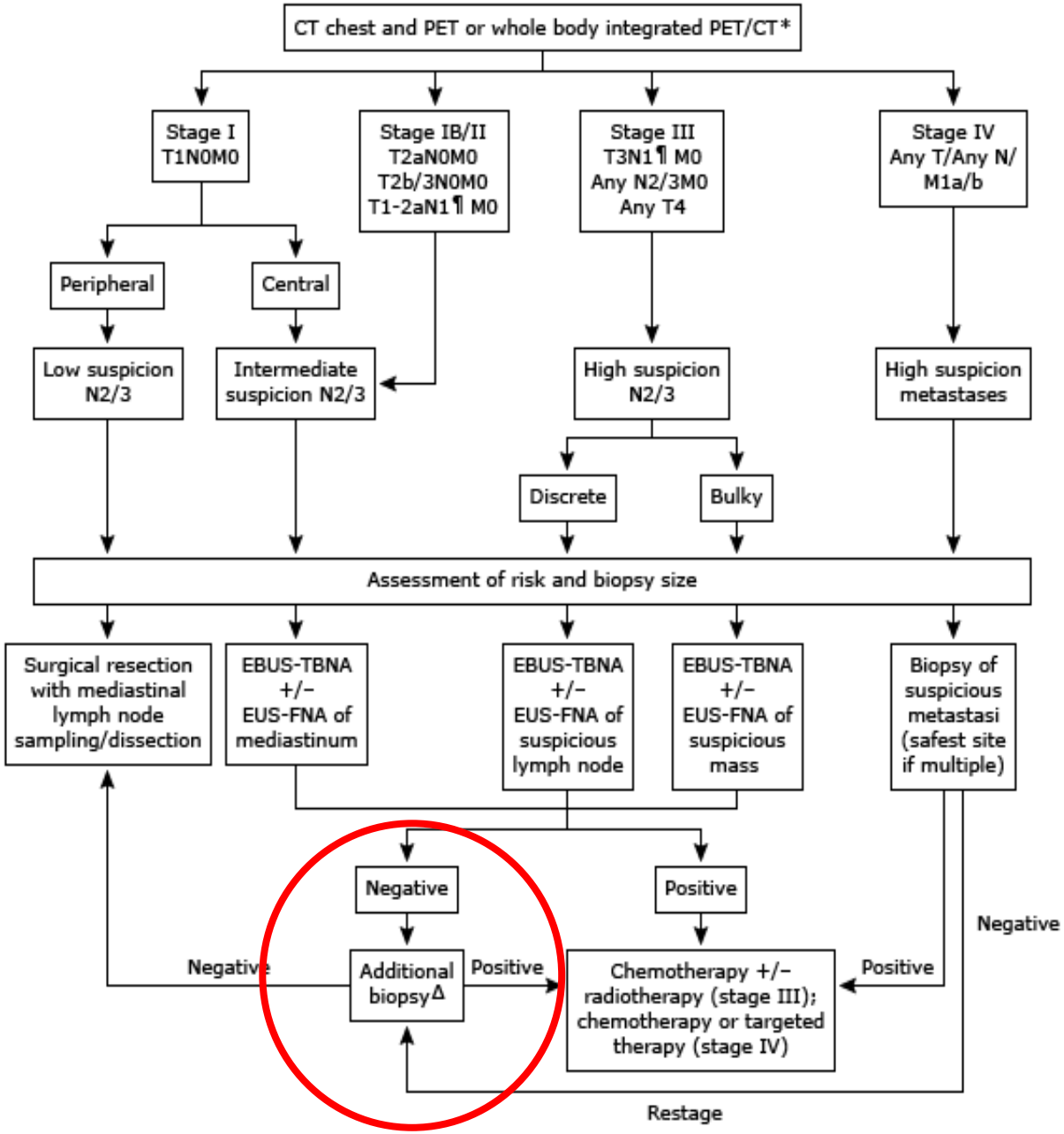

EBUS – EUS vs Μεσοθωρακοσκόπηση

Mediastinoscopy Endosonography for Mediastinal Nodal Staging of Lung Cancer

A Randomized Trial FREE

Jouke T. Annema, MD, PhD; Jan P. van Meerbeeck, MD, PhD; Robert C. Rintoul, FRCP, PhD; Christophe Dooms,

Table 2. Diagnostic Performance[a]

	No./Total No. (%) [95% Confidence Interval]		
Nodal Invasion, N2/N3	Surgical Staging (n = 118)	Endosonography and Surgical Staging (n = 123)	*P* Value
Sensitivity	41/52 (79) [66-88]	62/66 (94) [85-98]	.02
Negative predictive value	66/77 (86) [76-92]	57/61 (93) [84-97]	.18

JAMA. 2010;304(20):2245-2252.

EBUS – EUS vs Μεσοθωρακοσκόπηση

Mediastinoscopy Endosonography for Mediastinal Nodal Staging of Lung Cancer

A Randomized Trial FREE

Jouke T. Annema, MD, PhD; Jan P. van Meerbeeck, MD, PhD; Robert C. Rintoul, FRCP, PhD; Christophe Dooms,

Table 2. Diagnostic Performance[a]

	No./Total No. (%) [95% Confidence Interval]		
Nodal Invasion, N2/N3	Surgical Staging (n = 118)	Endosonography and Surgical Staging (n = 123)	*P* Value
Sensitivity	41/52 (79) [66-88]	62/66 (94) [85-98]	.02
Negative predictive value	66/77 (86) [76-92]	57/61 (93) [84-97]	.18

JAMA. 2010;304(20):2245-2252.

Ογκολογικό συμβούλιο

Αλλάζει το πλάνο σταδιοποίησης και αντιμετώπισης στο 26 – 40% των περιπτώσεων

Κλινικές περιπτώσεις

1. Ενδοβρογχική βλάβη
2. Εντοπισμένη παρεγχυματική βλάβη
3. Διάχυτη παρεγχυματική βλάβη
4. Μεσοθωρακική βλάβη
5. Πρώιμη διάγνωση καρκίνου πνεύμονα

Κλινικές περιπτώσεις

1. Ενδοβρογχική βλάβη

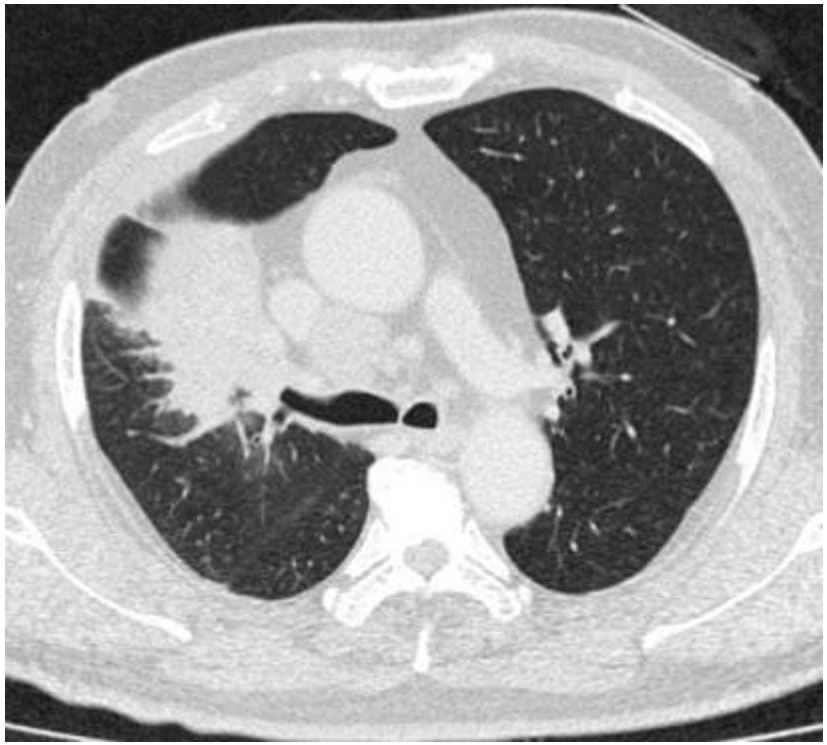

Κλινικές περιπτώσεις

1. Ενδοβρογχικές βλάβες

   α) εξωφυτικές

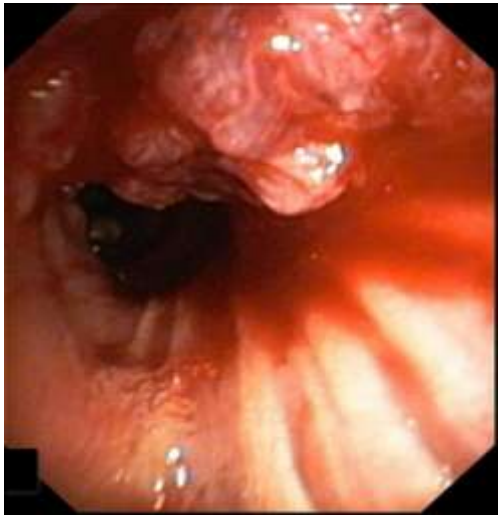

ΒΡΟΓΧΙΚΑ ΕΚΠΛΥΜΑΤΑ (WASHING)

Κυτταρολογική εξέταση ➔ 20 ml

Μικροβιολογική εξέταση ➔ 15 ml

ΒΡΟΓΧΙΚΑ ΞΕΣΜΑΤΑ (BRUSHING)

Κυτταρολογική εξέταση

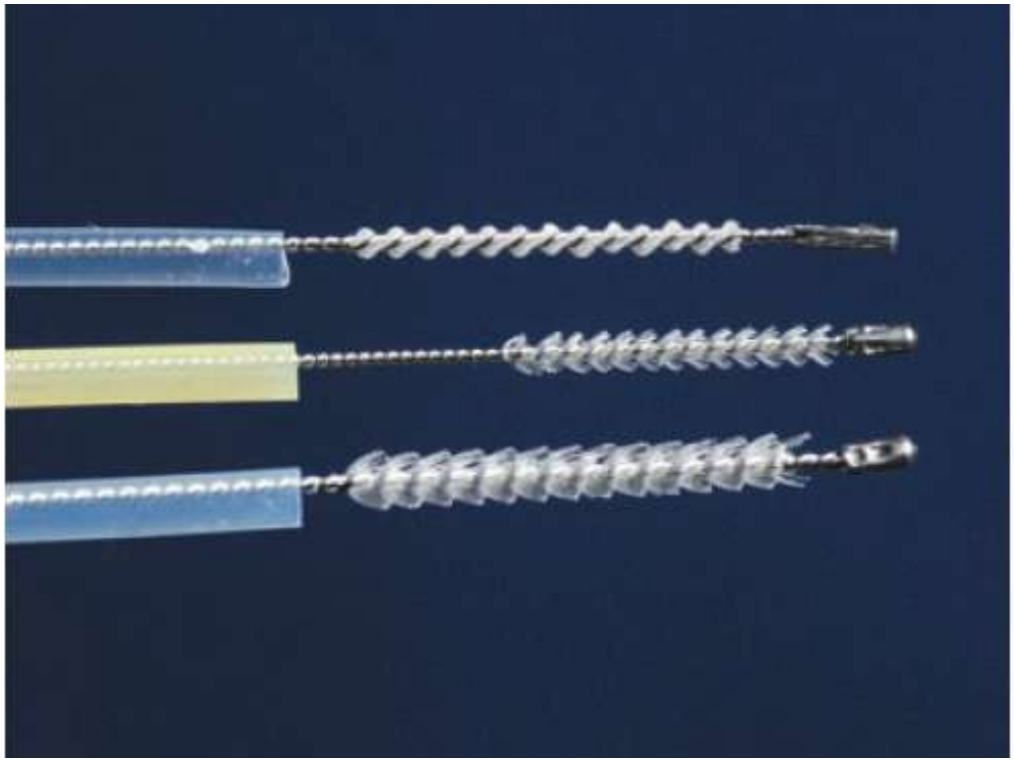

ΕΝΔΟΒΡΟΓΧΙΚΗ ΒΙΟΨΙΑ

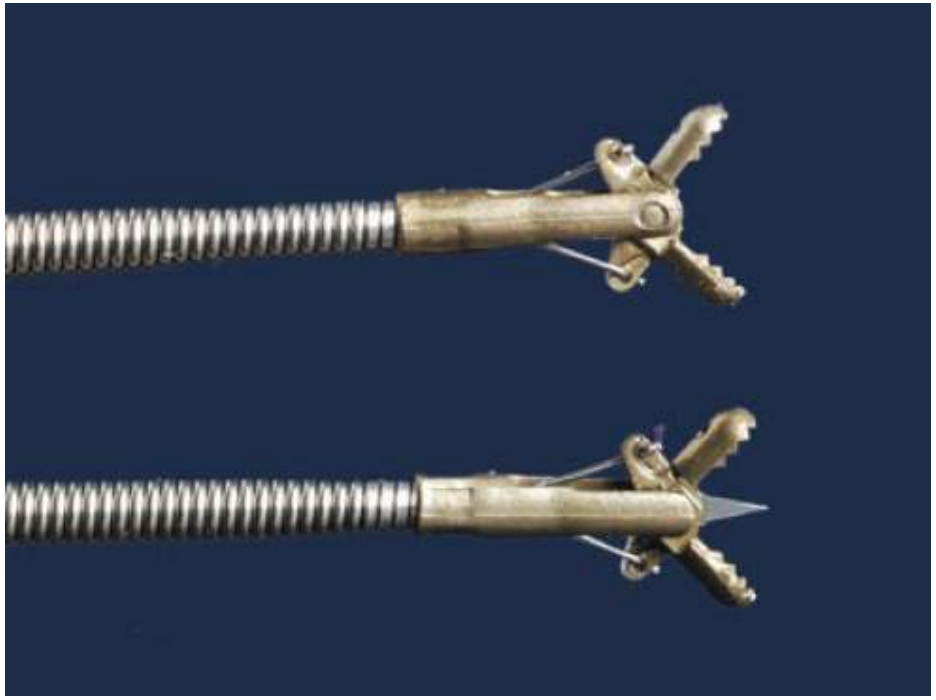

ΕΝΔΟΒΡΟΓΧΙΚΗ ΒΙΟΨΙΑ

Συνήθως 5 δείγματα

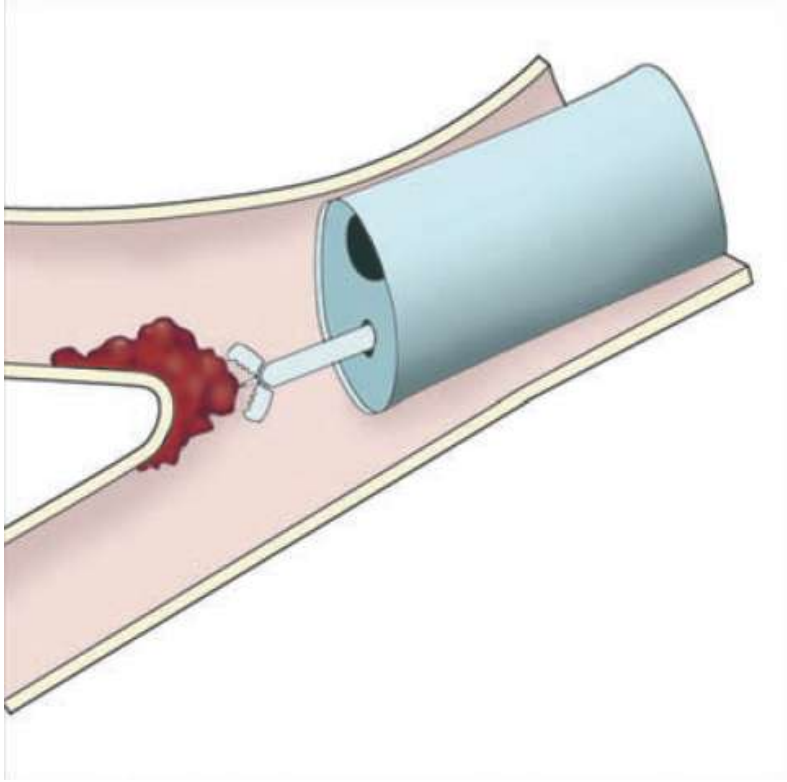

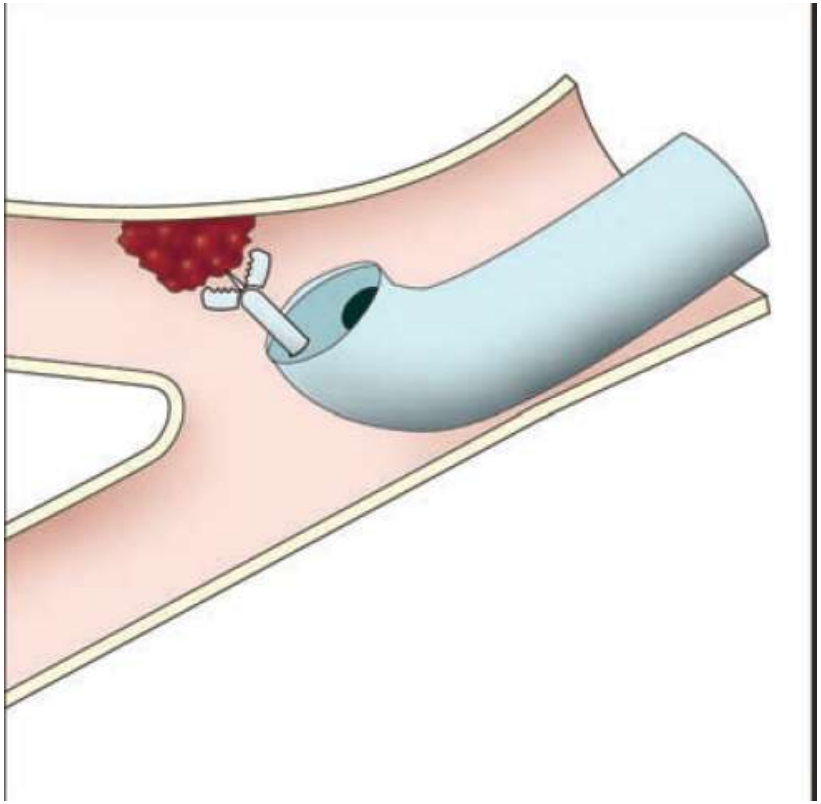

ΕΝΔΟΒΡΟΓΧΙΚΗ ΒΙΟΨΙΑ

Νέκρωση

Πολλαπλές βιοψίες από την ίδια περιοχή

ΕΝΔΟΒΡΟΓΧΙΚΗ ΒΙΟΨΙΑ

Αγγειοβριθής βλάβη

- ➔ Διάλυμα αδρεναλίνης πριν τη βιοψία
- ➔ Λαβίδα βιοψίας με ηλεκτροκαυτηρία (hot biopsy forceps)
- ➔ Άκαμπτο βρογχοσκόπιο

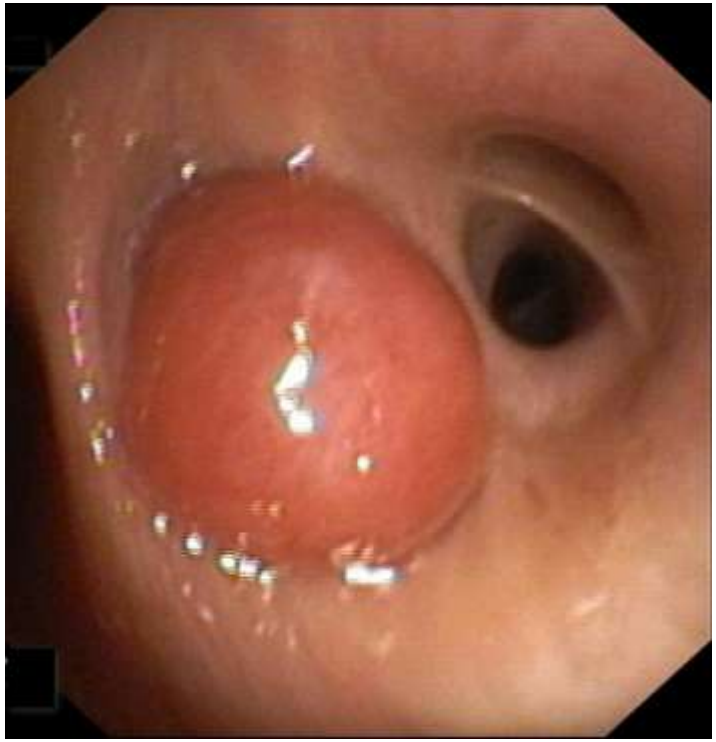

ΕΝΔΟΒΡΟΓΧΙΚΗ ΠΑΡΑΚΕΝΤΗΣΗ ΜΕ ΒΕΛΟΝΑ (ΕΒΝΑ)

1. Ενδοβρογχικές βλάβες
   β) υποβλεννογόνιες

Πολλαπλές βιοψίες από την ίδια περιοχή

ΕΝΔΟΒΡΟΓΧΙΚΗ ΠΑΡΑΚΕΝΤΗΣΗ ΜΕ ΒΕΛΟΝΑ (ΕΒΝΑ)

Ιστολογική βελόνα19G

Κυτταρολογική βελόνα 21G

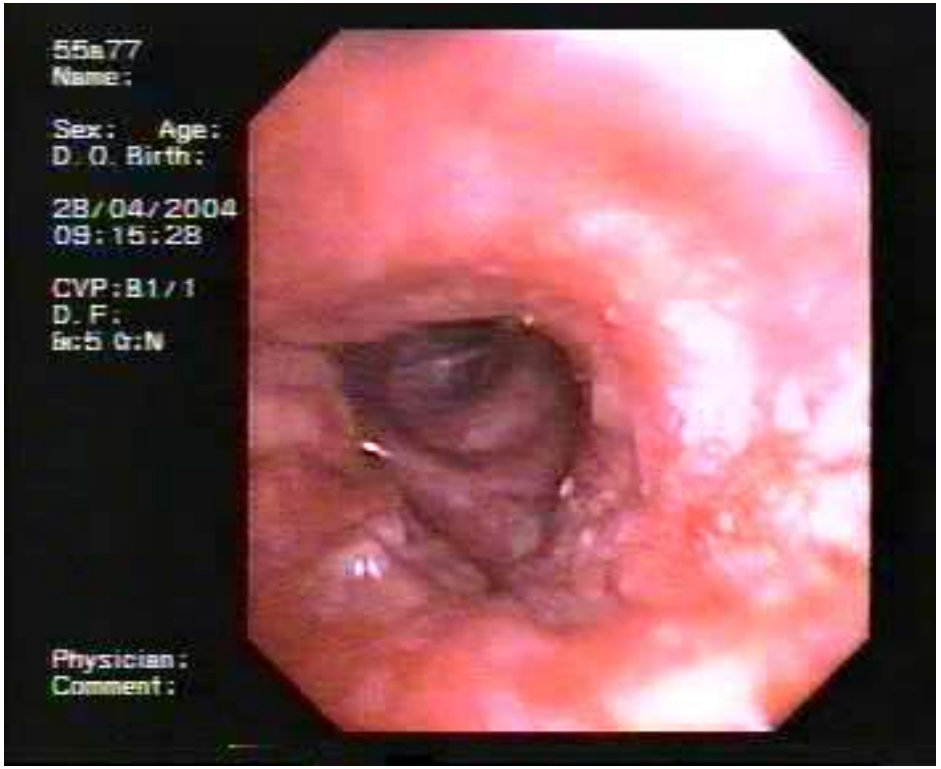

ΕΝΔΟΒΡΟΓΧΙΚΗ ΠΑΡΑΚΕΝΤΗΣΗ ΜΕ ΒΕΛΟΝΑ (EBNA)

- Αύξηση της διαγνωστικής ευαισθησίας από 76% σε 96% με την προσθήκη EBNA
- Στο 20% ήταν η μόνη διαγνωστική εξέταση

Dasgupta A. et al. Chest 1999;115:1237-1241

Διάγνωση καρκίνου του πνεύμονα
Κεντρική βλάβη

Table 2—*Sensitivity of FB Diagnostic Procedures for Central Bronchogenic Carcinoma**

Study/Year	Patients,† No.	Sensitivity				
		All Methods	Endobronchial Biopsy	Brush	Wash	EBNA/TBNA
Hsu et al[86]/2004	24					0.71
Win et al[87]/2003	78	0.85	0.61	0.27	0.45	0.42
Gaber et al[88]/2002	39	0.90	0.79	0.74	0.54	
Karahalli et al[89]/2001	98	0.90	0.83	0.68	0.32	0.69
Jones et al[90]/2001	514	0.89	0.72	0.72	0.48	
Baaklini et al[51]/2000	22	0.82				
Bungay et al[52]/2000	24	0.92				
Dasgupta et al[53]/1999	32	0.97				0.78
Govert et al[54]/1999	57	0.95	0.74		0.63	0.82
McLean et al[55]/1998	71		0.82			
Bilaceroglu et al[56]/1997	68	0.96		0.66		0.90
Sing et al[43]/1997	53			0.64		
Govert et al[57]/1996	177	0.85	0.81	0.48	0.43	
Castella et al[58]/1995	39					0.87
Utz et al[14]/1993	88					0.36
Buccheri et al[59]/1991	708		0.80	0.35	0.31	
Popp et al[60]/1991	99		0.93	0.79		
Mak et al[61]/1990	125	0.87	0.76	0.52	0.50	
Gay and Brutinel[62]/1989	53					0.23
Saita et al[63]/1989	105		0.48	0.30		
Wagner et al[44]/1989	72	0.67	0.58	0.39	0.35	0.36
Schenk et al[45]/1987	91	0.71	0.56	0.40	0.29	0.45
Cox et al[64]/1984	33	0.94	0.84	0.83	0.76	
Lam et al[65]/1983	329	0.94	0.82	0.74	0.76	
Zisholtz and Eisenberg[66]/1983	51	0.73	0.67	0.65	0.44	
Gellert et al[67]/1982	218		0.78			
Pilotti et al[46]/1982	286			0.78		
McDougall and Cortese[68]/1981	16		0.50	0.23		
Radke et al[69]/1979	15	0.87				
Chaudhary et al[47]/1978	95		0.76	0.53	0.78	
Chopra et al[48]/1977	51		0.66	0.72	0.51	
Stringfield et al[70]/1977	78		0.85			
Kvale et al[71]/1976	71		0.71	0.77	0.63	
Zavala[72]/1975	193	0.94	0.97	0.93		
Oswald et al[50]/1971	434		0.61			
Summary	4,507	0.88	0.74	0.61	0.47	0.56

Diagnosis and Management of Lung Cancer: ACCP Guidelines 2013

Διάγνωση καρκίνου του πνεύμονα
Κεντρική βλάβη

Ευαισθησία 88%

(EBB 74%, Brush 61%, Wash 47%, EBNA 56%)

Table 2—*Sensitivity of FB Diagnostic Procedures for Central Bronchogenic Carcinoma**

		Sensitivity				
Study/Year	Patients,† No.	All Methods	Endobronchial Biopsy	Brush	Wash	EBNA/TBNA
Summary	4,507	0.88	0.74	0.61	0.47	0.56

Diagnosis and Management of Lung Cancer: ACCP Guidelines 2013

Κλινικές περιπτώσεις

2. Εντοπισμένες παρεγχυματικές βλάβες

ΔΙΑΒΡΟΓΧΙΚΗ ΒΙΟΨΙΑ

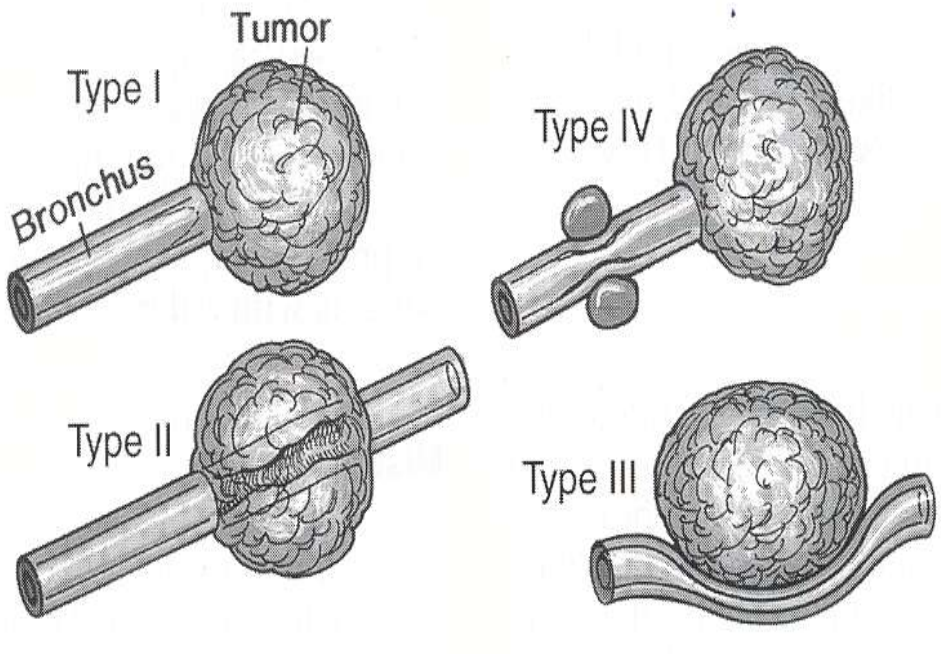

Tsuboi

- Σχέση με βρόγχο (I ή II)
- Μέγεθος (>2 cm)
- Σημείο βρόγχου (+)
- Εντόπιση (έσω 2/3)

ΔΙΑΒΡΟΓΧΙΚΗ ΒΙΟΨΙΑ

Υπό ακτινοσκόπηση (εντοπισμένες βλάβες)

- Μεγάλη ακτινοβολία
- Δεν παρέχει αίσθηση βάθους (2D απεικόνιση)
- Είναι η συνήθης μέθοδος με ευαισθησία 36% - 86% για μονήρεις όζους
- 7 – 8 δείγματα (BTS)

ΔΙΑΒΡΟΓΧΙΚΗ ΒΙΟΨΙΑ

- 4-6 δείγματα (BTS), ποτέ αμφοτερόπλευρα
- Αιμορραγία >50 ml (2 – 9%)
- Πνευμοθώρακας (1 – 6%)

ΔΙΑΒΡΟΓΧΙΚΗ ΒΙΟΨΙΑ

Πνευμονική υπέρταση

Σημαντική υποξυγοναιμία

Υπό μηχανική αναπνοή

Πνευμονεκτομή

ΔΙΑΒΡΟΓΧΙΚΗ ΒΙΟΨΙΑ

Περιφερικές βλάβες

Βρογχοκυψελιδικό έκπλυμα

Υπό ακτινοσκόπηση

Περιφερικό brushing

Παρακέντηση με βελόνα

Διάγνωση περιφερικής βλάβης

Table 3—*Sensitivity of FB Diagnostic Procedures for Peripheral Bronchogenic Carcinoma*

Study/Year	Patients,* No.	Sensitivity				
		All Methods	Transbronchial Biopsy	Brush	BAL	TBNA
Kawaraya et al[62]/2003	1,372	0.88	0.77	0.57		0.35
Trkanjec et al[66]/2003	50	0.86	0.62	0.16	0.29	
Bandoh et al[60]/2003	97	0.60				
Baba et al[64]/2002	87	0.75	0.53	0.44		0.67
Baahlini et al[61]/2000	129	0.61				
Gasparini et al[73]/1999	480	0.76	0.50			0.70
Reichenberger et al[74]/1999	103		0.39	0.36	0.28	0.47
Aristiazabal et al[75]/1998	64		0.34			
Bilaceroglu et al[76]/1998	92	0.64				
Wongsuralsiat et al[77]/1998	30	0.50	0.17		0.47	
Sing et al[45]/1997	22			0.22		
Castella et al[68]/1995	45					0.69
Debeljak et al[78]/1994	39		0.77	0.59	0.36	
de Gracia et al[79]/1993	55				0.33	
Torrington and Kern[80]/1993	91		0.20			
Utz et al[14]/1993						
Pirozynski[81]/1992	145		0.33	0.30	0.65	0.58
Buccheri et al[82]/1991	337		0.75	0.44	0.33	
Popp et al[83]/1991	87		0.80	0.83		
Mak et al[61]/1990	63	0.56	0.37	0.29	0.38	
Rennard et al[62]/1990	730				0.47	
Gay and Brutinel[62]/1989	20					0.65
Wagner et al[84]/1989						
Mori et al[85]/1989	85	0.84		0.84	0.42	
Naidich et al[84]/1988	65	0.48				
Cox et al[84]/1984	22	0.36	0.29	0.22	0.36	
Lam et al[86]/1983	155	0.86	0.61	0.52	0.52	
Pilotti et al[46]/1982	84			0.29		
Wallace and Deutsch[87]/1982	143		0.19			
McDougall and Cortese[88]/1981	130	0.62	0.48	0.36	0.36	
Radke et al[89]/1979	82	0.51				
Stringfield et al[70]/1977	29		0.48			
Kvale et al[71]/1976	29		0.27	0.21	0.12	
Zavala[72]/1975	137	0.71	0.69	0.70		
Hattori et al[49]/1971	208			0.83		
Oswald et al[90]/1971	435		0.28			
Summary	5,742	0.78	0.57	0.54	0.43	0.65

Diagnosis and Management of Lung Cancer: ACCP Guidelines 2013

Διάγνωση περιφερικής βλάβης

Ευαισθησία 78%

(TBB 57%, Brush 54%, BAL 43%, TBNA 65%)

Table 3—*Sensitivity of FB Diagnostic Procedures for Peripheral Bronchogenic Carcinoma*

		Sensitivity				
Study/Year	Patients,* No.	All Methods	Transbronchial Biopsy	Brush	BAL	TBNA
Summary	5,742	0.78	0.57	0.54	0.43	0.65

Diagnosis and Management of Lung Cancer: ACCP Guidelines 2013

ΠΕΡΙΦΕΡΙΚΕΣ ΒΛΑΒΕΣ

Localization

Navigation

ΠΕΡΙΦΕΡΙΚΕΣ ΒΛΑΒΕΣ

Localization

Navigation

Ενδοβρογχικό υπερηχογράφημα

Ενδοβρογχικός καθετήρας (Miniprobe)

- Λήψη βιοψιών από περιφερικές βλάβες

Ενδοβρογχικό υπερηχογράφημα

Ενδοβρογχικό υπερηχογράφημα

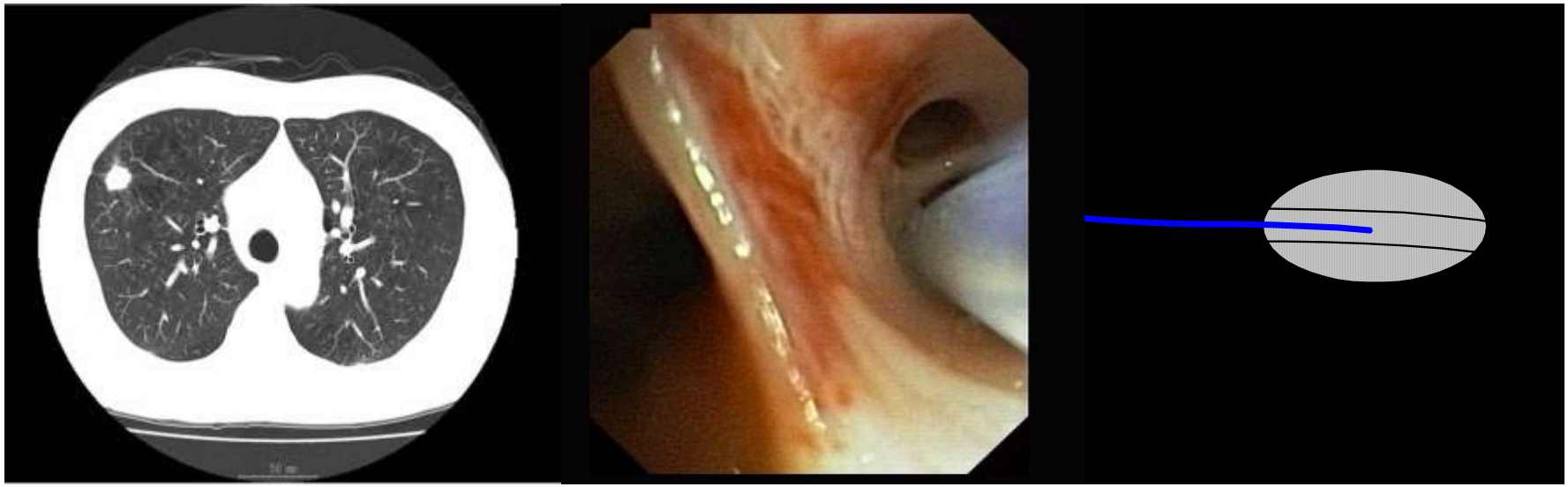

Ενδοβρογχικό υπερηχογράφημα

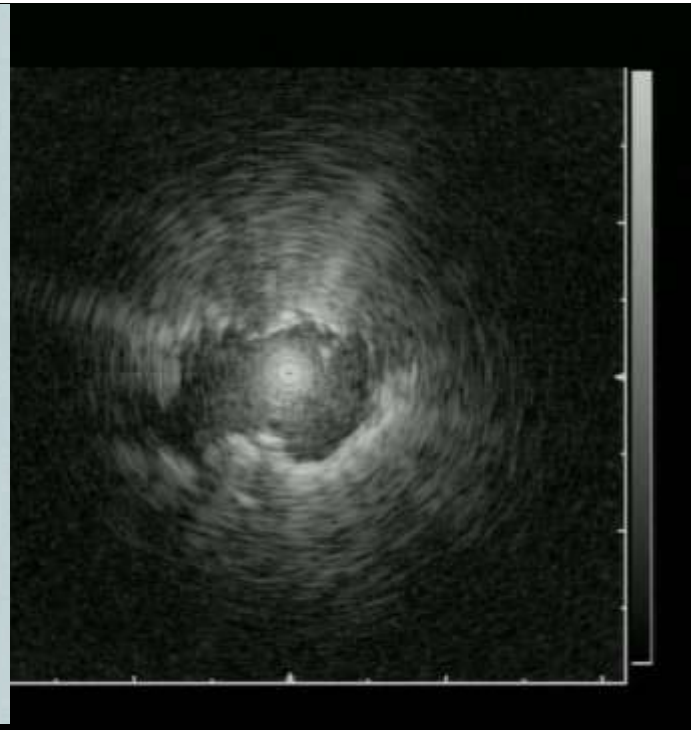

EBUS-guided biopsy SPN

- EBUS better <3cm SPN (80% vs 57%)
- No complications with EBUS-TBBX. Pneumothorax 1.4% of fluoroscopy-TBBX
- EBUS: No radiation exposure

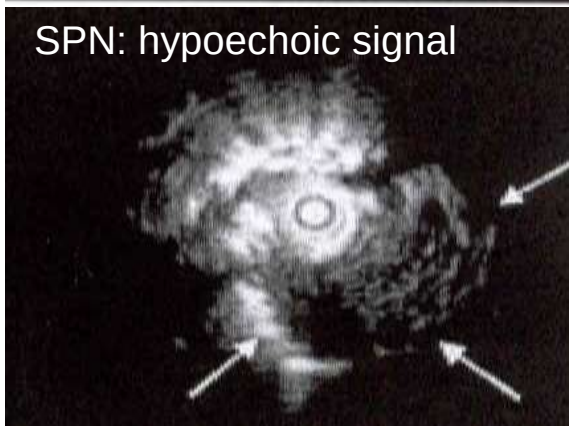

Herth et al. ERJ 2002

EBUS guided sheath for peripheral lesions

- Overall yield 77%, malignant 81%, benign 69%
- Nodules ≤10mm, yield= 76%
- Probe within 87% of SPN

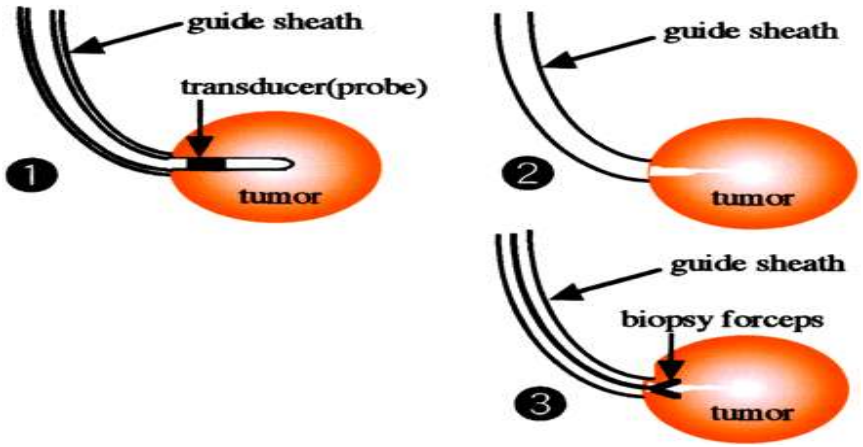

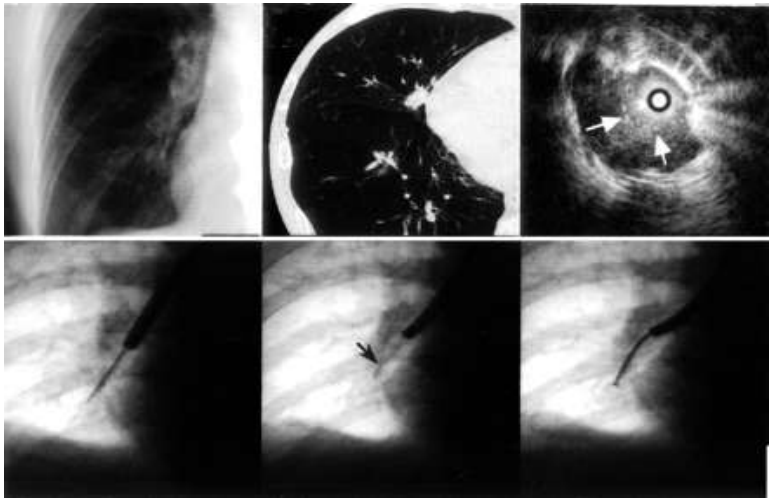

Kurimoto et al. Chest 2004

ΠΕΡΙΦΕΡΙΚΕΣ ΒΛΑΒΕΣ

Localization

Navigation

Ηλεκτρομαγνητική καθοδήγηση (electromagnetic navigation)

Βρογχοσκόπηση εντός μαγνητικού πεδίου

Αισθητήρας θέσης

Εκτεταμένο κανάλι εργασίας

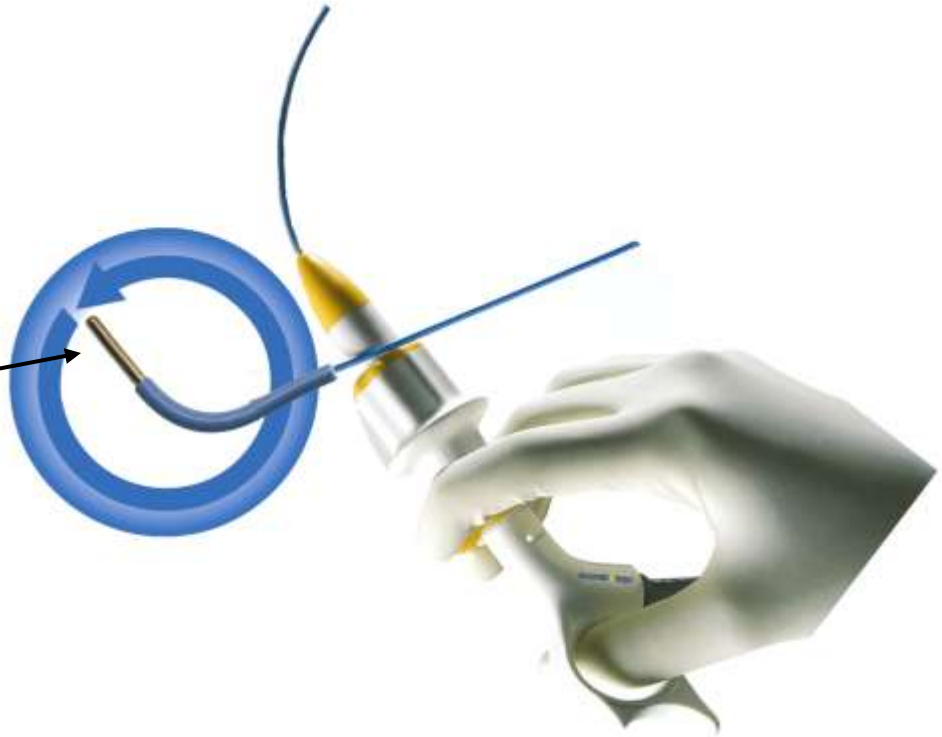

Ηλεκτρομαγνητική καθοδήγηση (electromagnetic navigation)

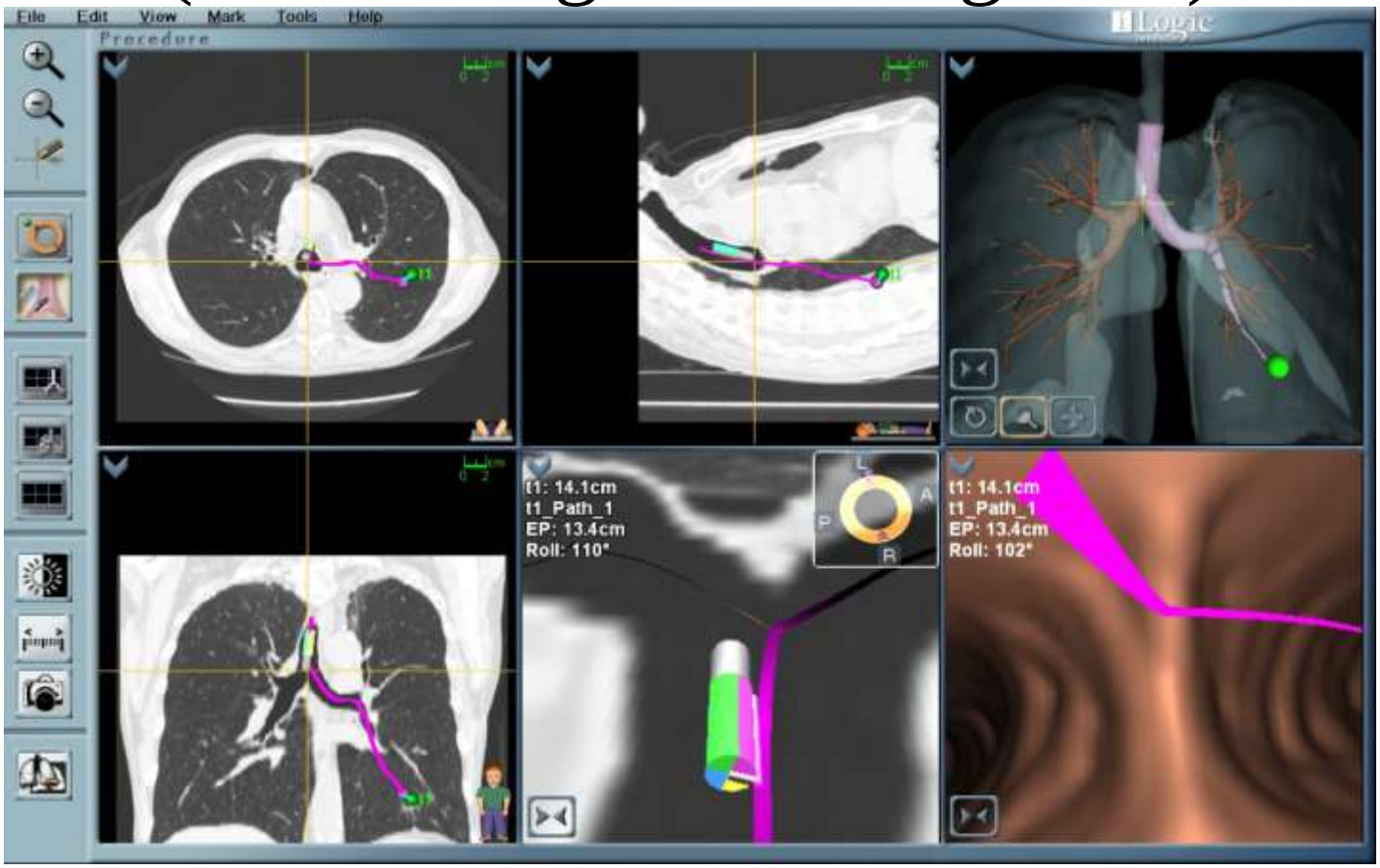

Electromagnetic Navigation Bronchoscopy

- ENB diagnostic yield 63 - 77 %
- Independent of
  - lobar distribution
  - lesion size
- Combination tools: forceps, brush
- Pneumothorax: 2-3%

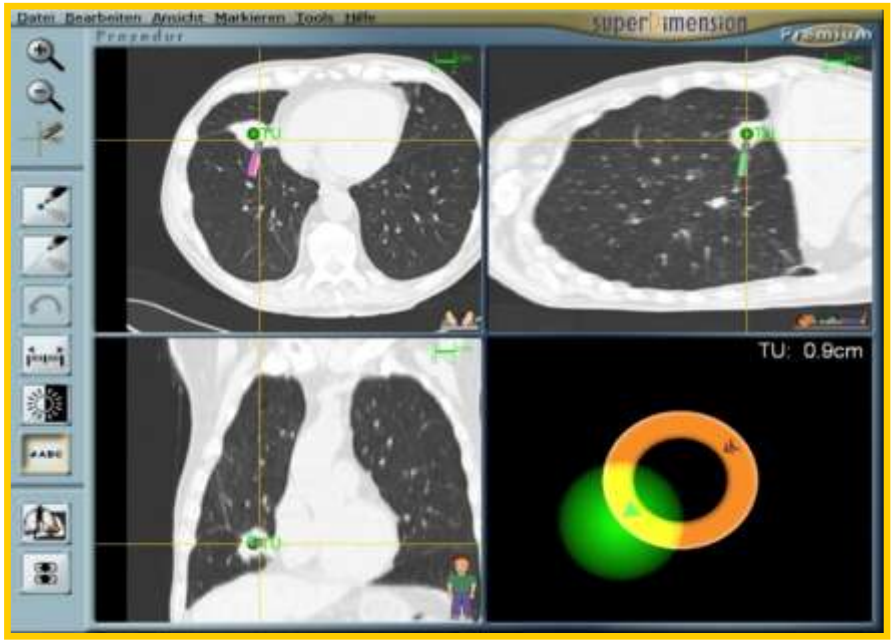

Electromagnetic Navigation Bronchoscopy + EBUS

- ENB diagnostic yield 63 - 77 %
- Independent of
  - lobar distribution
  - lesion size
- Combination tools: forceps, brush
- Pneumothorax: 2-3%

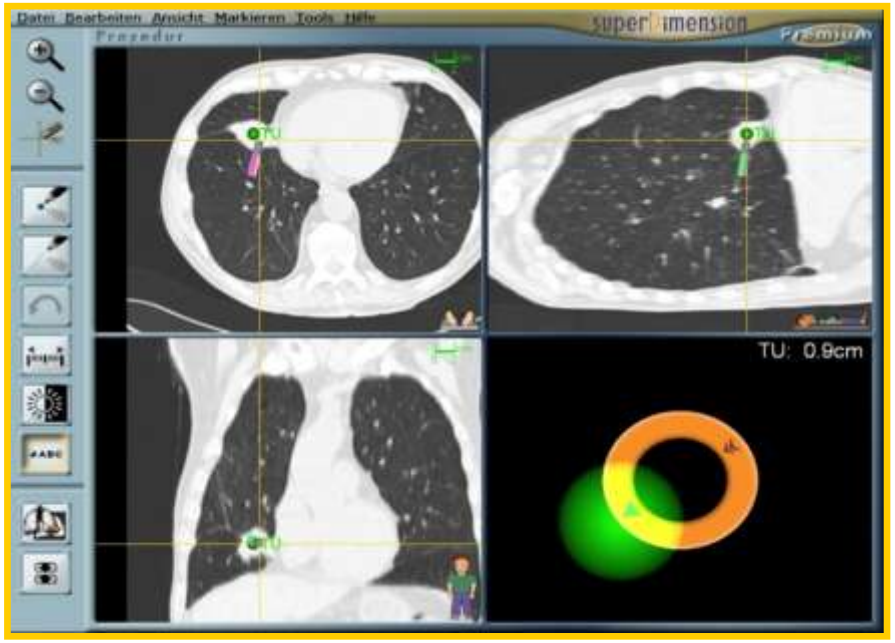

	EBUS n (%)	ENB n (%)	EBUS and ENB n (%)	p
Overall diagnostic yield	27/39 (69)	23/39 (59)	35/40 (88)	0.02†

Eberhardt et al AJRCCM 2007

Καθοδήγηση με αξονική τομογραφία (CT navigation)

Υπέρλεπτα βρογχοσκόπια με κανάλι εργασίας (d=2.8 mm)

Έως 9ης γενιάς βρόγχους

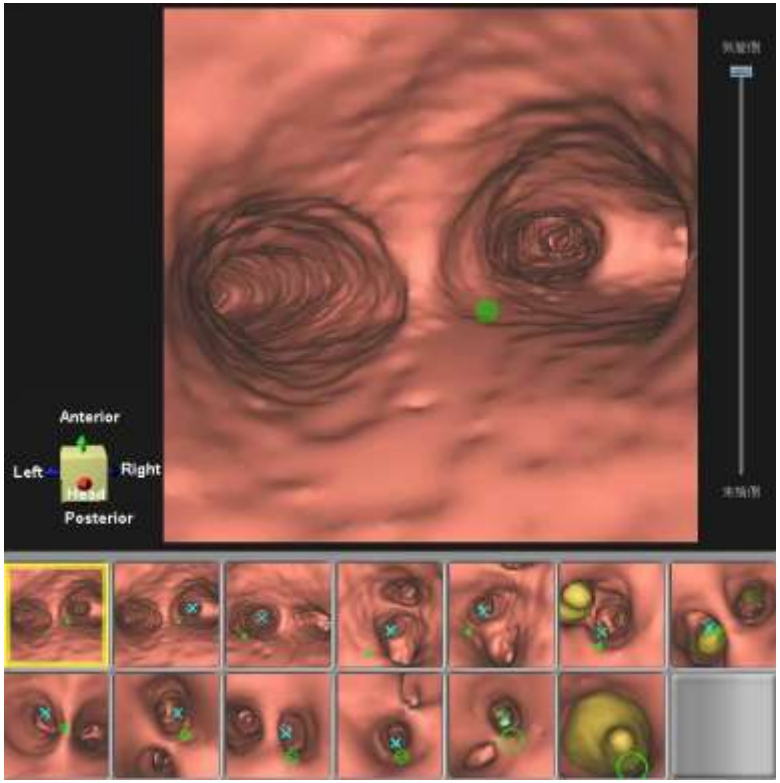

Καθοδήγηση με αξονική τομογραφία (CT navigation)

DirectPath™
Ziostation™
LungPoint™
Synapse Vincent™
etc

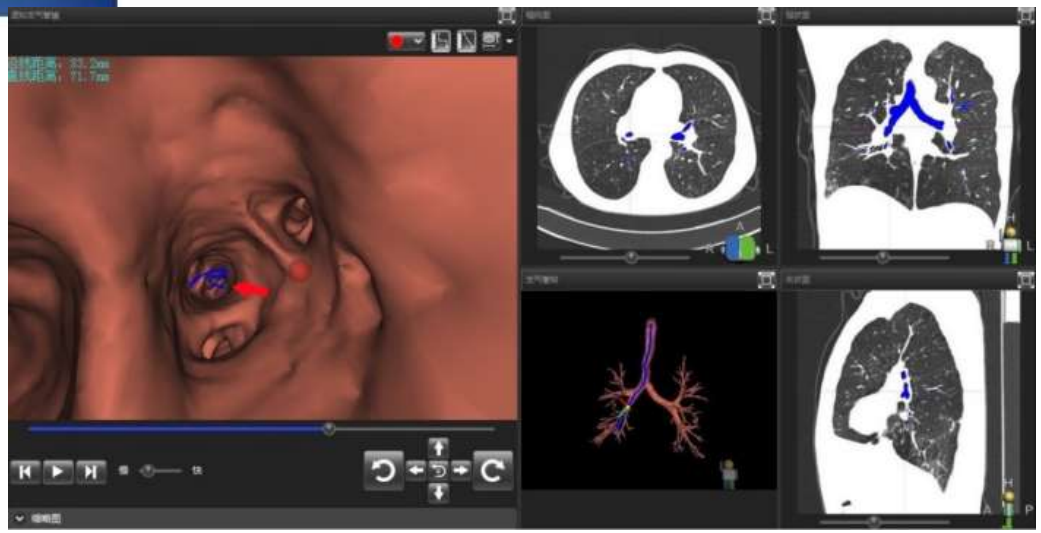

Virtual fluoroscopy during transbronchial biopsy for locating ground-glass nodules not visible on X-ray fluoroscopy

Toshiyuki Nakai[1], Takehiro Izumo[2], Yuji Matsumoto[1], Takaaki Tsuchida[1]

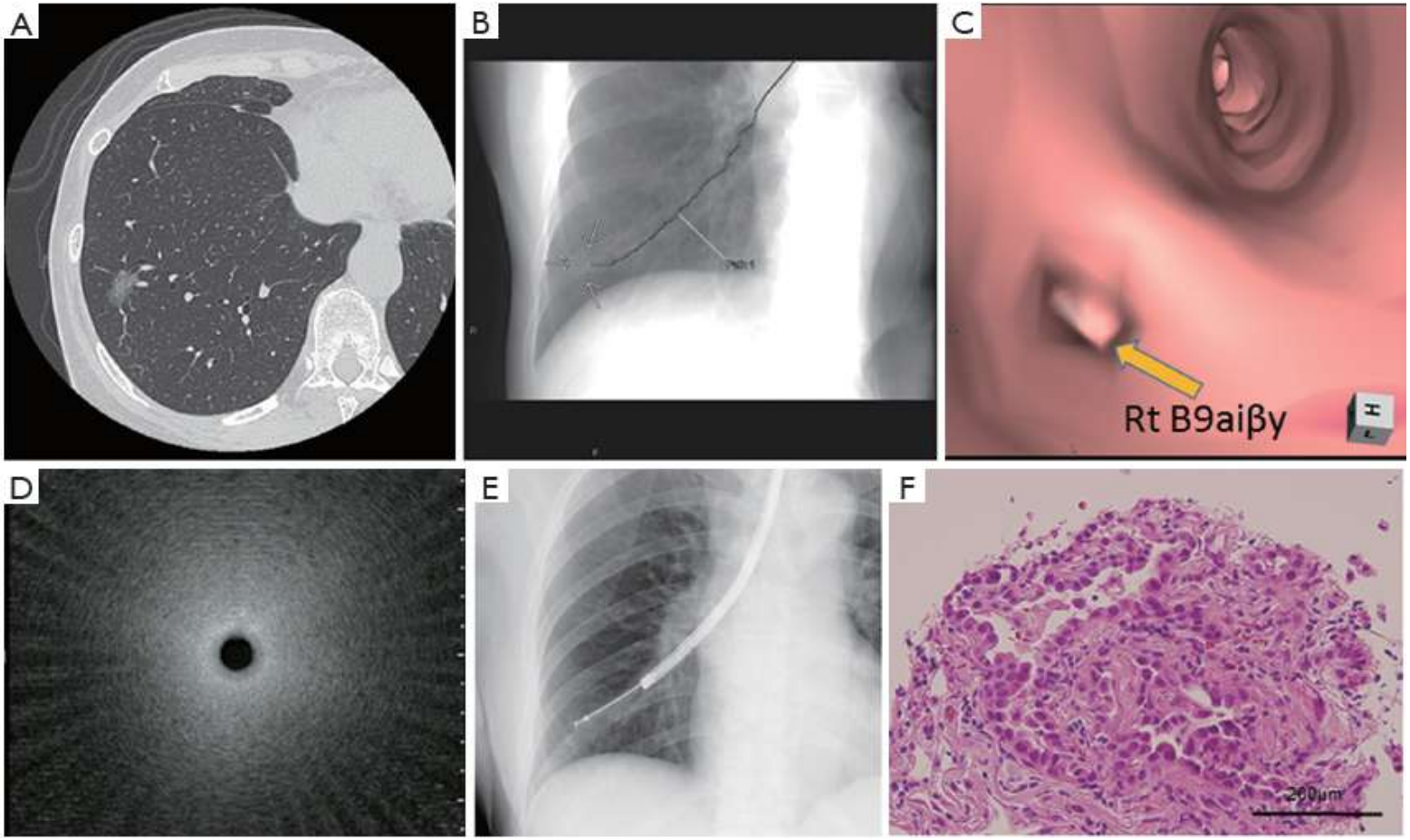

J Thorac Dis 2017;9(12):5493-5502

Bronchoscopic navigation

+ EBUS

Comparison of Diagnostic Accuracy in Radial EBUS Transbronchial Lung Biopsy Under Navigation Versus CT-Guided Percutaneous Needle Biopsy: A Meta-Analysis

Jung Hyun Chang , Yeji Han , Soo

Results: From 14854 records, 8 papers with 1 group, while 11 papers with 2359 procedures were retrieved for CT group unde of age and sex. The size of nodule was 6 to 107 mm for the former and 11 to 120 mm confidence interval [CI] 72-76%) in BF group and 88% (95% CI: 87-89%) in CT group. nd the latter was 70% (95% CI: 62-78%) and 88% (95% CI: 86-90%), respectively. Whe oup was 88% (95% CI: 80-93%) in the former and 95% (95% CI: 93-97%) in the latte procedures in BF group: rate of pneumothorax was 0.8%, hemoptysis 0.1%, a plications were noted in 1000 (42.4%) among 2359 procedures: rate of pneumothor %.

Conclusion: The diagnostic yield of CT-PCNB 3. However, when the nodule size was over 20mm, the accuracy of BF approach was ty, the events of pneumothorax and hemorrhage were reported much higher in C arried both advantages and disadvantages in terms of diagnostic accuracy and safety, the decision making can be considered according to the clinical situation and equipment status of the institution.

BF	accuracy 74%	complications 1,3%
CT	accuracy 88%	complications 42,4%

ATS 2017
Where today's science meets tomorrow's care™

J Chang et al AJRCCM 2017;195:A2871

STAR WARS

Your Eyes Can Deceive You: Don't Trust them

Evidence based Update on Diagnsotic Yield in the periphery

Starring:

Gerard Silvestri
Medical University of South Carolina
Yoda

Hans Lee
Johns Hopkins University
Boba Fett

Nichole Tanner
Medical University of South Carolina
Princess Leia

Alexander Chen
Washington University of St Louis
Strom Trooper

Bronchoscopy Yield

CHEST
AMERICAN COLLEGE of CHEST PHYSICIANS

Study	Sites/Patients	Yield/Sensitivity
2015 AQuIRE registry	15 sites 531 patients	Flexible bronchoscopy – 64% Radial EBUS – 57% EMN – 39%
2015 AEGIS study	28 sites 639 patients	Overall – 53% for diagnosis of cancer
2018 Multicenter RCT standard bronchoscope with fluoroscopy (SB-F) vs thin bronchoscope with radial EBUS (TB-EBUS)	5 sites 221 patients	Overall – 44% SB-F – 37% TB-EBUS – 49% > 3cm – 57%

Ost et al. *AJRCCM*, 2015
Silvestri et al. *NEJM*, 2015
Tanner et al. *CHEST*, 2018

CHEST™

Yield

CHEST
AMERICAN COLLEGE of CHEST PHYSICIANS

		Yield
Overall		69%
pCA	<10%	44%
	10-60%	42%
	>60%	77%
Bronchoscopy Type	Standard +/- Fluoro	55%
	EMN	57%
	EBUS	80%
	Standard + EBUS	83%
	Other combination	0%

		Yield
Size	<1cm	56%
	1-2cm	59%
	>2-<3cm	62%
	>3cm	78%
Location	Peripheral	52%
	Central	79%
	Central + Peripheral	76%
Lymphadenopathy	No	64%
	Yes	81%
Site Type	Academic	69%
	Community	64%
	VA	72%

CHEST™

Feasibility of the Lungvision Augmented Endobronchial Fluoroscopic Navigation and Localization System: Comparison With Cone Beam CT for Nodule Localization

Michael Pritchett

AUGMENTED REALITY NAVIGATION

RESULTS: 20 patients were included in the study with average age of 71.6+SD (range 48-85). Average lesion size was 21.7mm+SD (range 10-33mm), and 70% of the lesions were located in the upper lobes (RUL/LUL). No peri-procedural adverse events were reported. Successful navigation to the pulmonary nodule, according to LungVision display, was achieved in all cases. In 100% of cases (20 out of 20), the lesion size and location shown by the LungVision system matched CBCT imaging (accuracy 5mm+SD). Tissue samples were successfully acquired in all cases.

CONCLUSIONS: Augmented endobronchial fluoroscopic navigation is safe, feasible and provides lesion localization accuracy similar to CBCT-guided endobronchial biopsy.

CHEST Annual Meeting 2017

Oct 2017:152 (4) Suppl A863

Bronchoscopic Peripheral Lung Nodule Navigation by a Novel Live Endobronchial Fluoroscopic Navigation and Guidance Systemtechnology: Insights From the Multicenter Lungvision I Trial

AUGMENTED REALITY NAVIGATION

Sean Stoy, Douglas Hogarth, Akrum Al-Zubaidi, Patrick Whitten
University of Chicago Medical Center, Chicago, IL

CONCLUSIONS: Augmented endobronchial fluoroscopic navigation is safe, feasible and accurate real time lesion localization modality. Further large-scale studies are indicated to assess the possible role of LungVision as a potential method of choice for the image-guided biopsy of peripheral lung lesions.

CLINICAL IMPLICATIONS: Technologies that rely on virtual guidance rely on temporally remote imaging to chart a navigation pathway to peripheral lung nodules, this techonology which utilizes real-time real-nodule guidance represents a technological advancement and provides improved diagnostic accuracy.

CHEST Annual Meeting 2017

Oct 2017:152 (4) Suppl A757

Augmented Fluoroscopy

- For use with electromagnetic navigational bronchoscopy
- Overlays the navigational pathway onto the fluoroscopic image
- Available as a stand alone system or as additional add on software to cone beam CT scanners
  - Lung View
  - Phillips + OncoSuite
  - Siemens + syngo Fusion Package

CHEST™

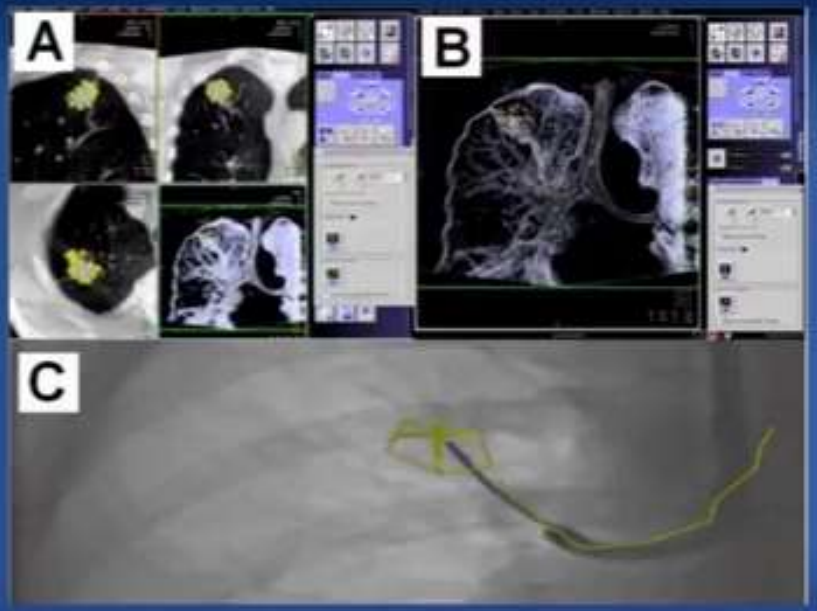

Hohenforst-Schmidt W, et al Journal of Cancer. 2014.

CHEST™

First Human Use of a New Robotic-Assisted Navigation System for Small Peripheral Pulmonary Nodules Demonstrates Good Safety Profile and High Diagnostic Yield

ROBOTIC NAVIGATION

David Fielding, Farzad Bashirzadeh, Jung Hua Son, Maryann Todman, Hau Tan, Adrian Chin, Karin Steinke, Morgan Windsor
Royal Brisbane and Womens Hospital, Brisbane, QLD, Australia

remote controlled 3mm diameter catheter

robotic-assisted catheter remains completely stationary during sampling

a newly developed, investigational flexible biopsy needle

.Overall diagnostic yield for these cases was 83%

CLINICAL IMPLICATIONS: The ability of the catheter and needle to reach distal airways and maintain static position allows unique sampling capability.

CHEST Annual Meeting 2017

Oct 2017:152 (4) Suppl A858

Currently Available System-Auris Monarch

- A robotically propelled outer sheath (5.7-mm) with an inner telescoping endoscope (4.4 mm)
- It uses electromagnetic navigation for guidance with an external EM field generator
- The physician uses a small hand-held controller to guide the robotic scope
- The scope has continuous optical capabilities and a separate suction channel (working channel 2.1 mm)

Pritchett, M. Journal of Thoracic Disease, 2018

Currently Available Systems- Intuitive

- An articulating, robotic-assisted catheter allows navigation along a planned path through the airways to a predetermined location
- This system uses a navigation system based on shape sensing technology, rather than the traditional electromagnetic
- The working channel of this biopsy channel is 2.0 mm

Bronchoscopic TransParenchymal Nodule Access: Evaluation of Safety and Feasibility of Archimedes System

Felix J. Herth , Shiyue Li , Jiayuan Sun , Daniel Nader ,

A. Creating a hole in the airway wall at point-of-entry with the FlexNeedle

B. Dilating the airway wall with the Archimedes Dilation Balloon

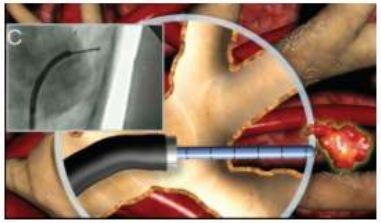

C. Tunnelling with the Archimedes Sheath and blunt stylet through parenchymaltissue using fused fluoroscopic guidance provided by the Archimedes System

D. Accessing sampling and/or treating the nodule with 2mm wording channel compatible bronchoscopic tools

CONCLUSIONS

Low complication risk and competitive process time suggest the benefits of using Archimedes System for BTPNA procedure in both community-based and teaching-based hospitals. There is an ongoing clinical study and more data will be presented to improve statistical confidence.

ATS 2017
Where today's science meets tomorrow's care™

FJ Herth, S Li, J Sun, D Nader; AJRCCM 2017;195:A7597

Κύριοι βρόγχοι ως αντιπρόσωποι
των περιφερικών βλαβών

(FIELD OF INJURY)

Leveraging the airway field of injury to assess the risk of lung cancer

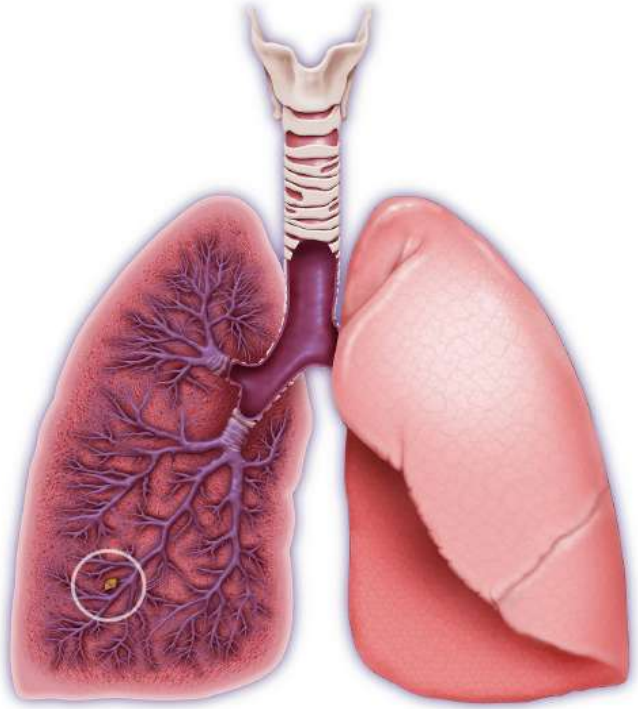

Smoking impacts airway gene expression

-***PNAS 2004; NAR 2005***

Subset of changes are irreversible upon smoking cessation

-***Genome Biology 2007***

Airway gene expression can serve as an early diagnostic biomarker for lung cancer

-***Nature Medicine 2007; CAPR 2008***

Bronchial airway gene expression is related to tumor tissue and normal adjacent tissue.

– ***JNCI 2013***

ORIGINAL ARTICLE

A Bronchial Genomic Classifier for the Diagnostic Evaluation of Lung Cancer

Gerard A. Silvestri, M.D., Anil Vachani, M.D., Duncan Whitney, Ph.D., Michael Elashoff, Ph.D., Kate Porta Smith, M.P.H., J. Scott Ferguson, M.D., Ed Parsons, Ph.D., Nandita Mitra, Ph.D., Jerome Brody, M.D., Marc E. Lenburg, Ph.D., and Avrum Spira, M.D., for the AEGIS Study Team*

N Engl J Med 2015;373:243-51.

AEGIS I &AEGIS II

Table 3. Performance of Bronchoscopy and the Classifier, Stratified According to the Pretest Probability of Cancer.*

Variable	Low Pretest Probability of Cancer (N=62)	Intermediate Pretest Probability of Cancer (N=101)	High Pretest Probability of Cancer (N=426)	Unknown Pretest Probability of Cancer (N=50)
Patients with lung cancer — no. (%)	3 (5)	41 (41)	405 (95)	38 (76)
Patients with benign lesions — no. (%)	59 (95)	60 (59)	21 (5)	12 (24)
Bronchoscopy performance				
Sensitivity — % (95% CI)	33 (1–91)	41 (26–58)	79 (74–82)	82 (66–92)
Patients with nondiagnostic bronchoscopic examination — no. (%)†	61 (98)	84 (83)	108 (25)	19 (38)
Classifier performance				
Sensitivity — % (95% CI)‡	100 (16–100)	88 (68–97)	89 (80–94)	100 (59–100)
Specificity — % (95% CI)§	56 (42–69)	48 (35–62)	29 (11–52)	33 (10–65)
Negative predictive value — % (95% CI)¶	100 (89–100)	91 (75–98)	38 (15–65)	100 (40–100)
Positive predictive value — % (95% CI)¶	7 (1–24)	40 (27–55)	84 (75–91)	47 (21–73)
Combined classifier and bronchoscopy sensitivity — % (95% CI)	100 (29–100)	93 (80–98)	98 (96–99)	97 (91–100)

N Engl J Med 2015;373:243-51.

Prospective Utility of a Bronchial Genomic Classifier for Lung Cancer Detection: Interim Results From a Multicenter Prospective Registry

Hans Lee* Patrick Whitten Krish Bhadra Travis Dotson Douglas Hogarth Sadia Benzaquen Michael Pritchett Joshiah Gordon Ajay Bedekar Mark Esterle Kate Smith Pauline Bianchi Marc Lenburg and Avrum Spira Veracyte, South San Francisco, CA

43 medical centers
665 eligible patients

CONCLUSIONS: This interim analysis from this prospective registry confirms the performance of the BGC reported in the AEGIS I and II studies.The emerging safety of reclassified low risk patients is encouraging. Additional follow-up is required to evaluate the full impact of clinical utility.

CLINICAL IMPLICATIONS: The BGC improves the sensitivity of diagnostic bronchoscopy for patients undergoing evaluation for lung cancer and can reduce the number of unnecessary invasive procedures that are performed following an inconclusive procedure.

CHEST Annual Meeting 2017

Oct 2017:152 (4) Suppl A625

Κλινικές περιπτώσεις

3. Διάχυτη παρεγχυματική βλάβη

ΔΙΑΒΡΟΓΧΙΚΗ ΒΙΟΨΙΑ

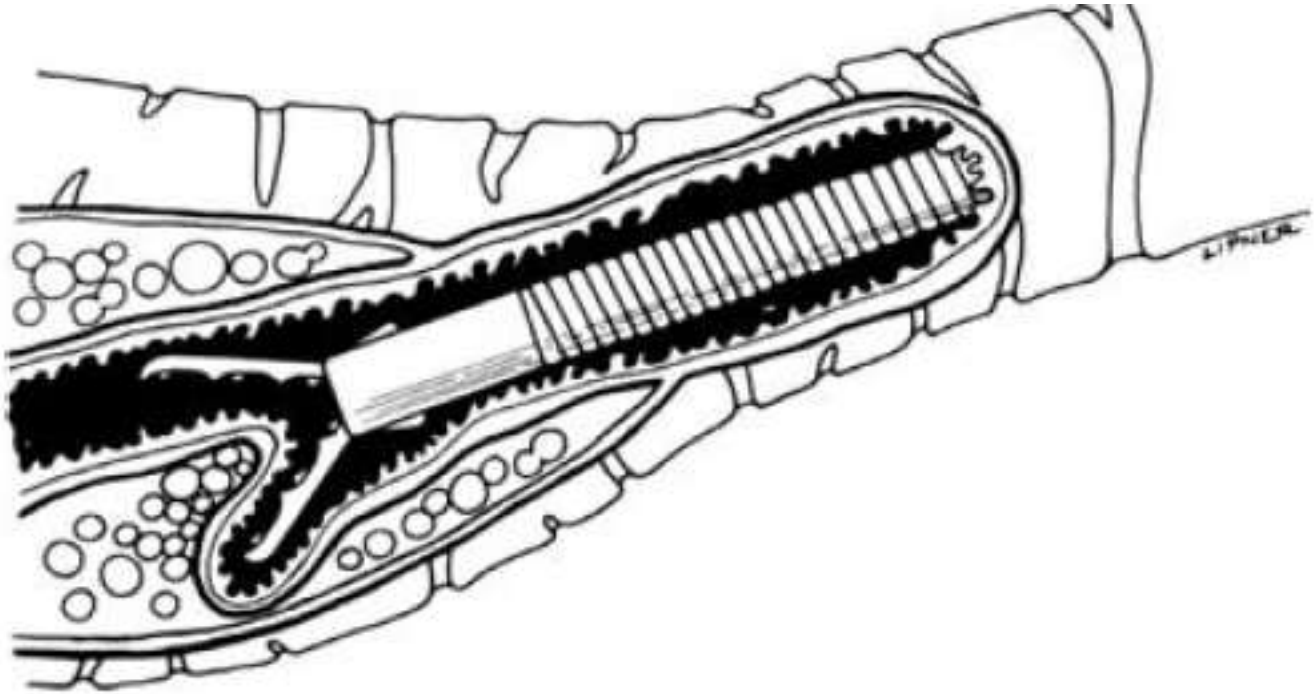

ΔΙΑΒΡΟΓΧΙΚΗ ΒΙΟΨΙΑ

Table 10.1. *Indications for TBB*
Sarcoidosis
Langerhans cell histiocytosis
Pulmonary alveolar proteinosis
Lipoid pneumonia
Eosinophilic pneumonia
Drug-induced pneumonitis
Pulmonary infiltrates in the immunocompromised host
Pulmonary carcinomatosis
Lymphangitic malignancy

ΒΡΟΓΧΟΚΥΨΕΛΙΔΙΚΟ ΕΚΠΛΥΜΑ (BAL)

- 100 – 200 ml (ανά 20 – 50 ml) μέσα από το κανάλι εργασίας ή από ειδικό καθετήρα σε 3ης με 4ης γενιάς βρόγχο
- Αναρρόφηση με σύριγγα ή χαμηλής πίεσης αναρρόφηση
- Επιθηλιακά κύτταρα < 5% και παρόντα κυψελιδικά μακροφάγα

ΒΡΟΓΧΟΚΥΨΕΛΙΔΙΚΟ ΕΚΠΛΥΜΑ (BAL)

Table 9.3. *Role of BAL in noninfectious diseases*

Diagnostic	Suggestive, not definitive
Pulmonary alveolar proteinosis	Alveolar hemorrhage
Langerhans cell histiocytosis	Asbestosis
Lipoid pneumonia/Fat embolism	Berylliosis
Malignancy	Drug-induced disease (amiodarone)
	Eosinophilic pneumonias
	Hypersensitivity pneumonitis
	Sarcoidosis
	Silicosis

Adapted from: *Am J Respir Crit Care Med.* 1990;142:481–486.

Κλινικές περιπτώσεις

4. Μεσοθωρακικές βλάβες

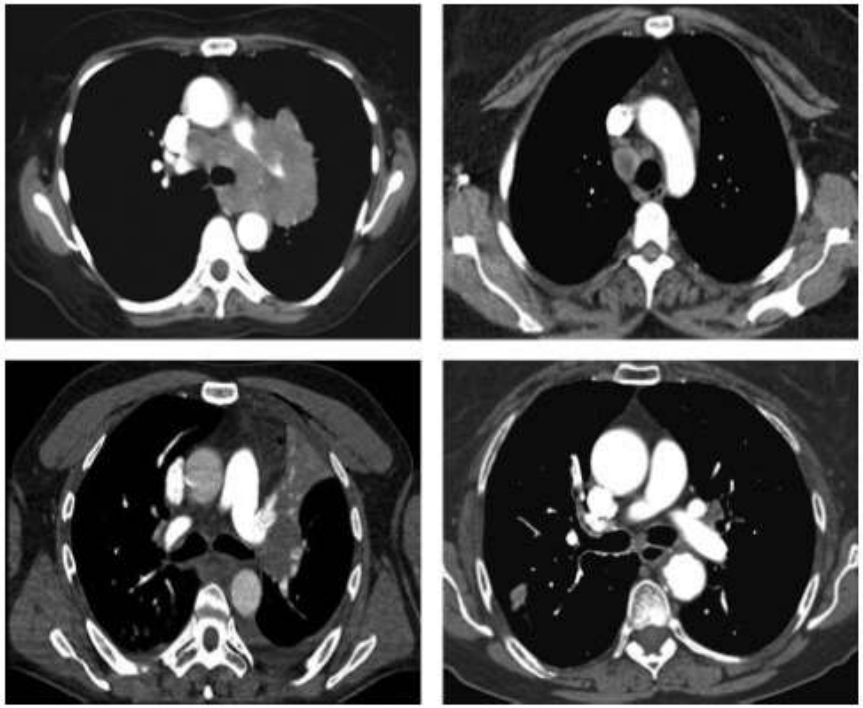

ΔΙΑΒΡΟΓΧΙΚΗ ΠΑΡΑΚΕΝΤΗΣΗ ΜΕ ΒΕΛΟΝΑ (TBNA)

Παρατραχειακά
(station 4R)
Αορτοπνευμονικό παράθυρο
(station 4L)
Υποτροπιδικά
(station 7)

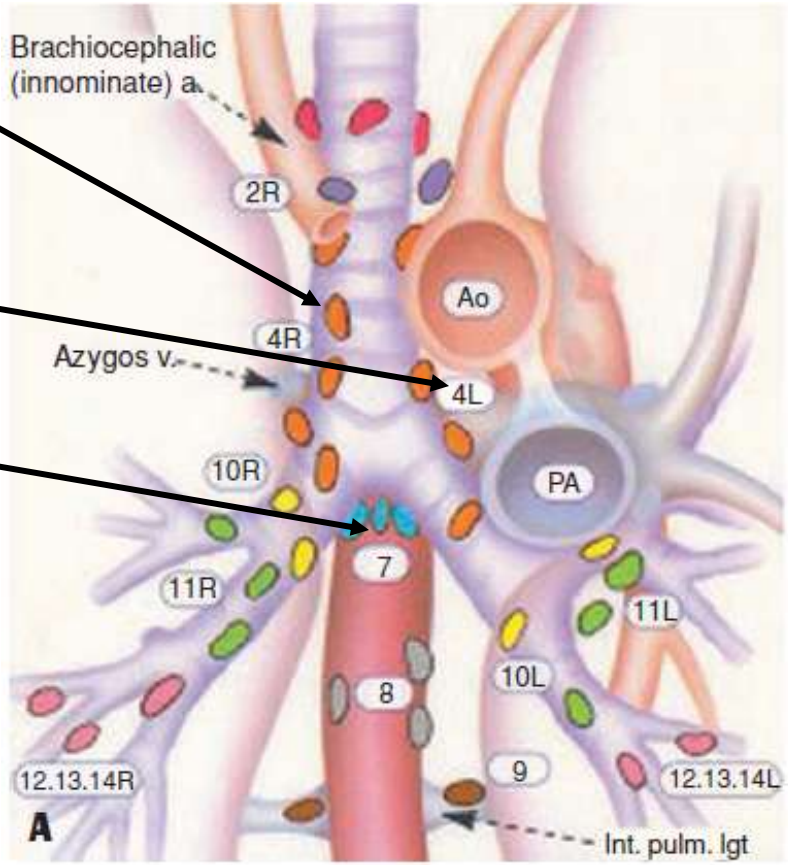

ΔΙΑΒΡΟΓΧΙΚΗ ΠΑΡΑΚΕΝΤΗΣΗ ΜΕ ΒΕΛΟΝΑ (TBNA)

Ιστολογική βελόνα19G

Κυτταρολογική βελόνα 21G

3 – 4 δείγματα

Ευαισθησία 40% - 80%

Σπάνιες επιπλοκές

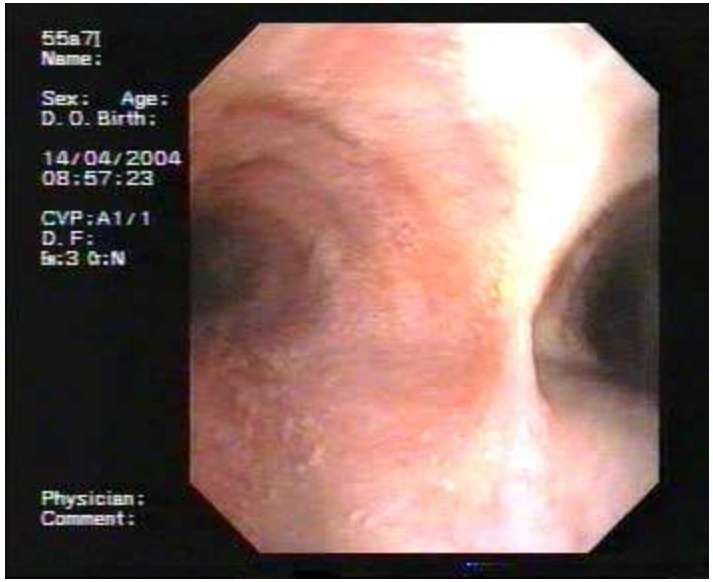

ΔΙΑΒΡΟΓΧΙΚΗ ΠΑΡΑΚΕΝΤΗΣΗ ΜΕ ΒΕΛΟΝΑ (TBNA)

Σπάνιες επιπλοκές



Ενδοβρογχικό υπερηχογράφημα

Υπερηχοβρογχοσκόπιο

- Λήψη υλικών από μεσοθωρακικές βλάβες
- Διαβρογχική παρακέντηση λεμφαδένων

Ενδοβρογχικό υπερηχογράφημα

Scopes: Olympus/ Pentax/ Fuijnon

Needles: Olympus/ Medi-Globe/ COOK/ Boston Scientific

Ultrasound: Olympus/ Hitachi/ Aloka/ Fuijnon

Ενδοβρογχικό υπερηχογράφημα

Έγχρωμο Doppler

Λεμφαδένες < 10 mm

Ευαισθησία 89%

NPV 91%

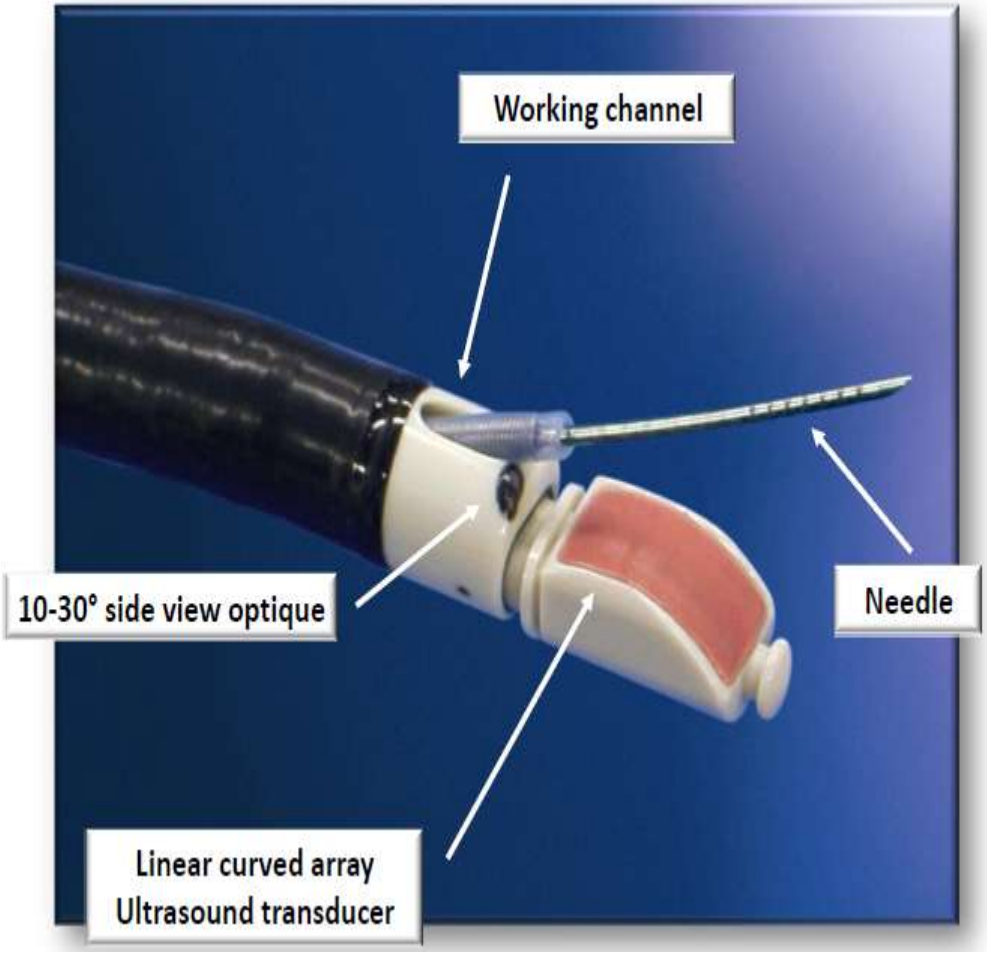

Diagnosis and Management of Lung Cancer: ACCP Guidelines 20

Ενδοβρογχικό υπερηχογράφημα

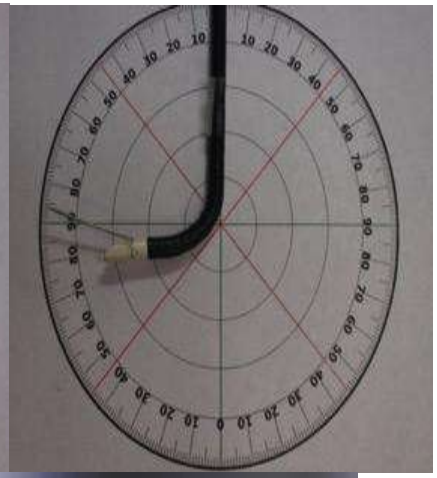



Various needles

- 19 gauge
- 21/22-gauge
- 25-gauge

EBUS: 6 landmarks

1. Trachea
2. 4L
3. 7
4. 10L
5. 10R
6. 4R



Ενδοβρογχικό υπερηχογράφημα

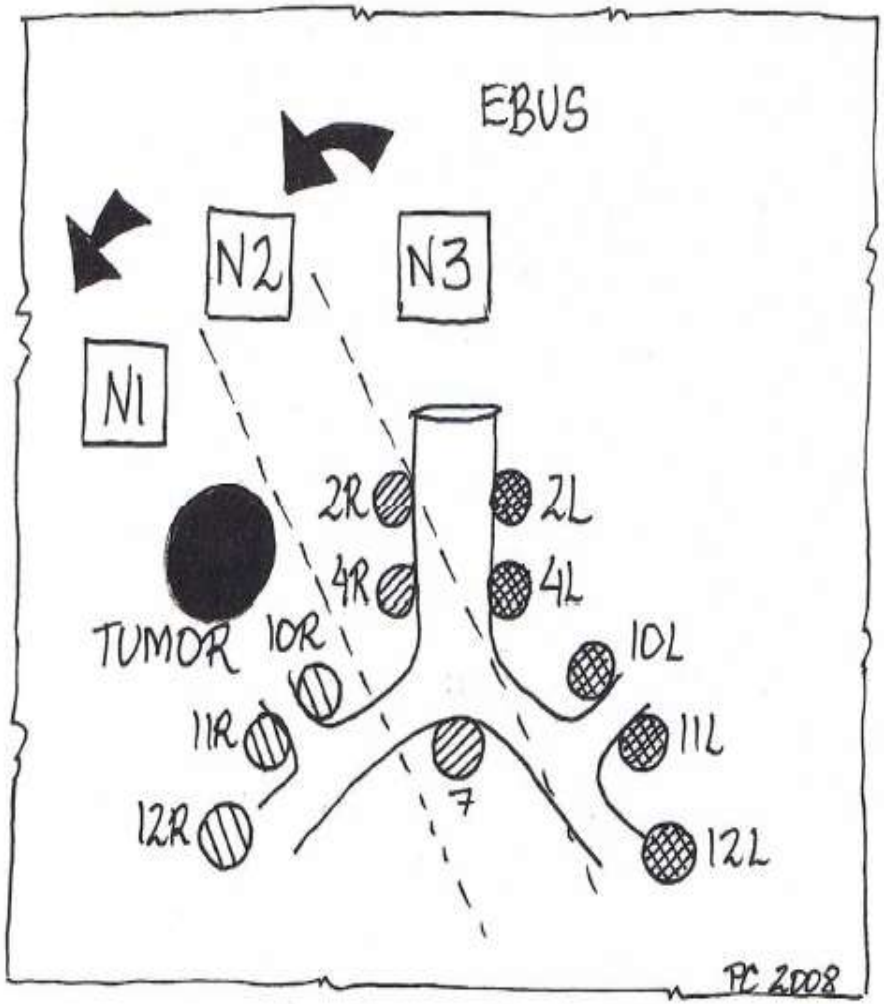

Ενδοβρογχικό υπερηχογράφημα

Κλινικές περιπτώσεις

5. Πρώιμη διάγνωση καρκίνου του πνεύμονα

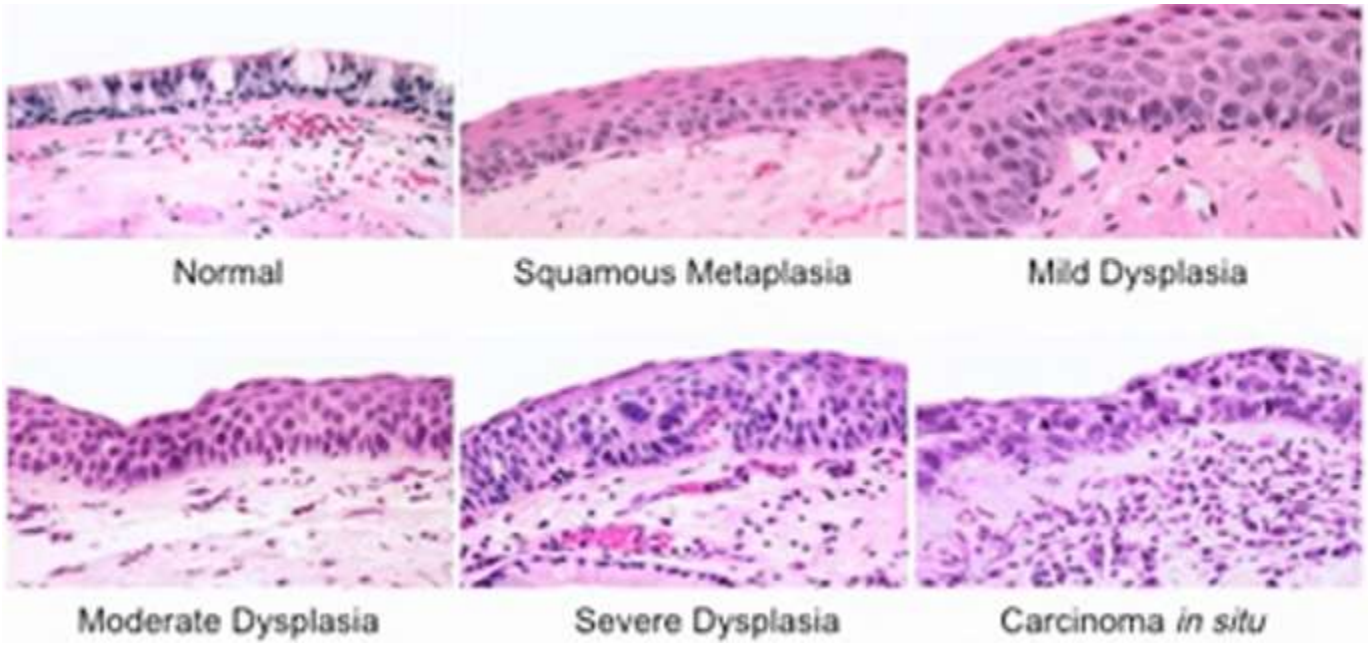

Bronchial Intraepithelial Neoplasia (IEN)

HGD/CIS

- 20-70% progression rate

IEN

- Risk factor for entire lung (field of injury)
- 5 year risk 32-44%
- 60-85% other sites

Van Boerdonk et al AJRCCM 2015

Πρώιμη διάγνωση καρκίνου του πνεύμονα

Detection of lesions

- White light bronchoscopy
- Autofluorescence bronchoscopy
- Narrow band imaging
- Raman spectroscopy

Depth of invasion

- Radial EBUS
- Optical coherence tomography

Πρώιμη διάγνωση καρκίνου του πνεύμονα

Detection of lesions

- White light bronchoscopy
- Autofluorescence bronchoscopy
- Narrow band imaging
- Raman spectroscopy

Depth of invasion

- Radial EBUS
- Optical coherence tomography

White light bronchoscopy

- Better image resolution and quality
- Low sensitivity
- Nodular or polypoid

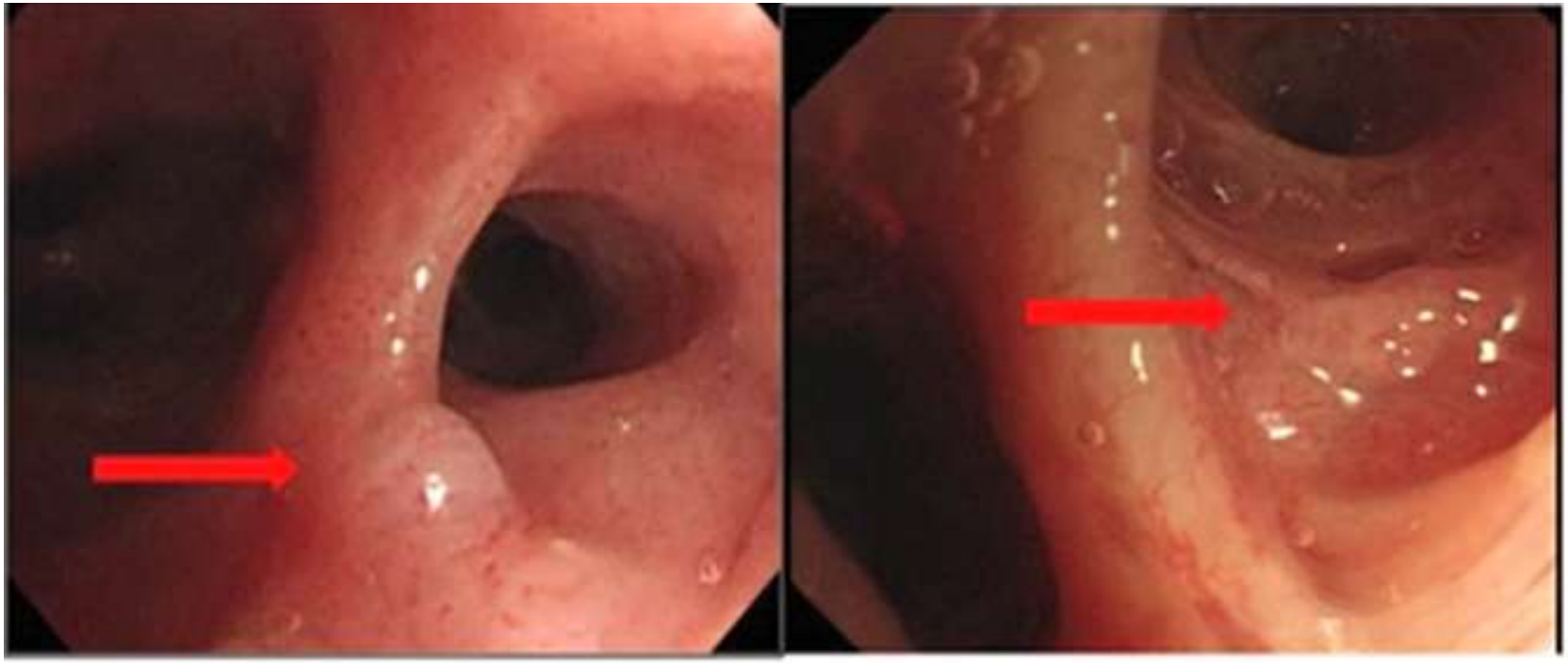

Shibuya Lung Cancer 2010

Πρώιμη διάγνωση καρκίνου του πνεύμονα

Detection of lesions

- White light bronchoscopy
- Autofluorescence bronchoscopy
- Narrow band imaging
- Raman spectroscopy

Depth of invasion

- Radial EBUS
- Optical coherence tomography

Αυτοφθορισμός

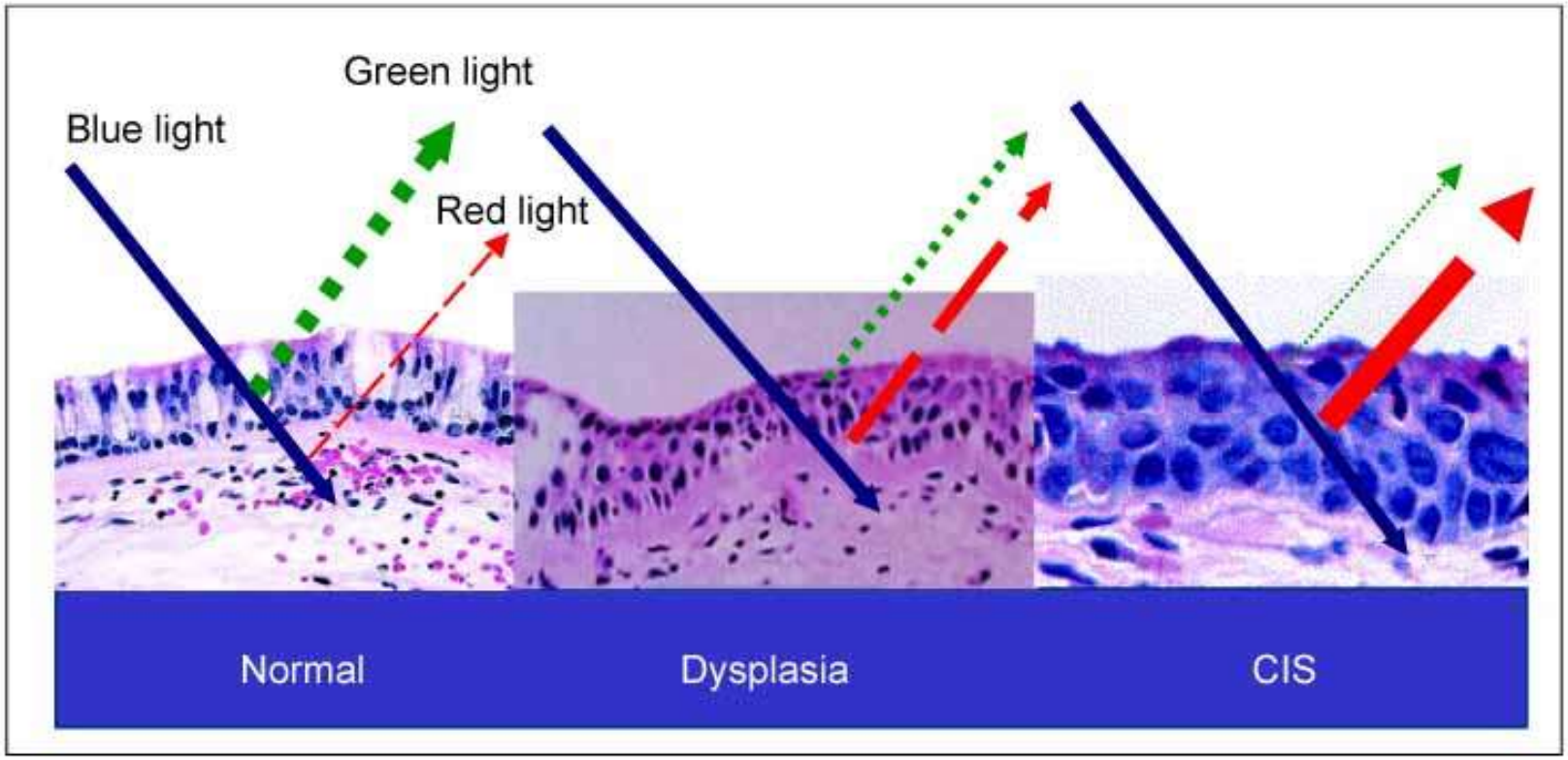

Αυτοφθορισμός

- WLB+AFB (sen x 2 43% vs 85%)
  (spe 80% vs 61%)

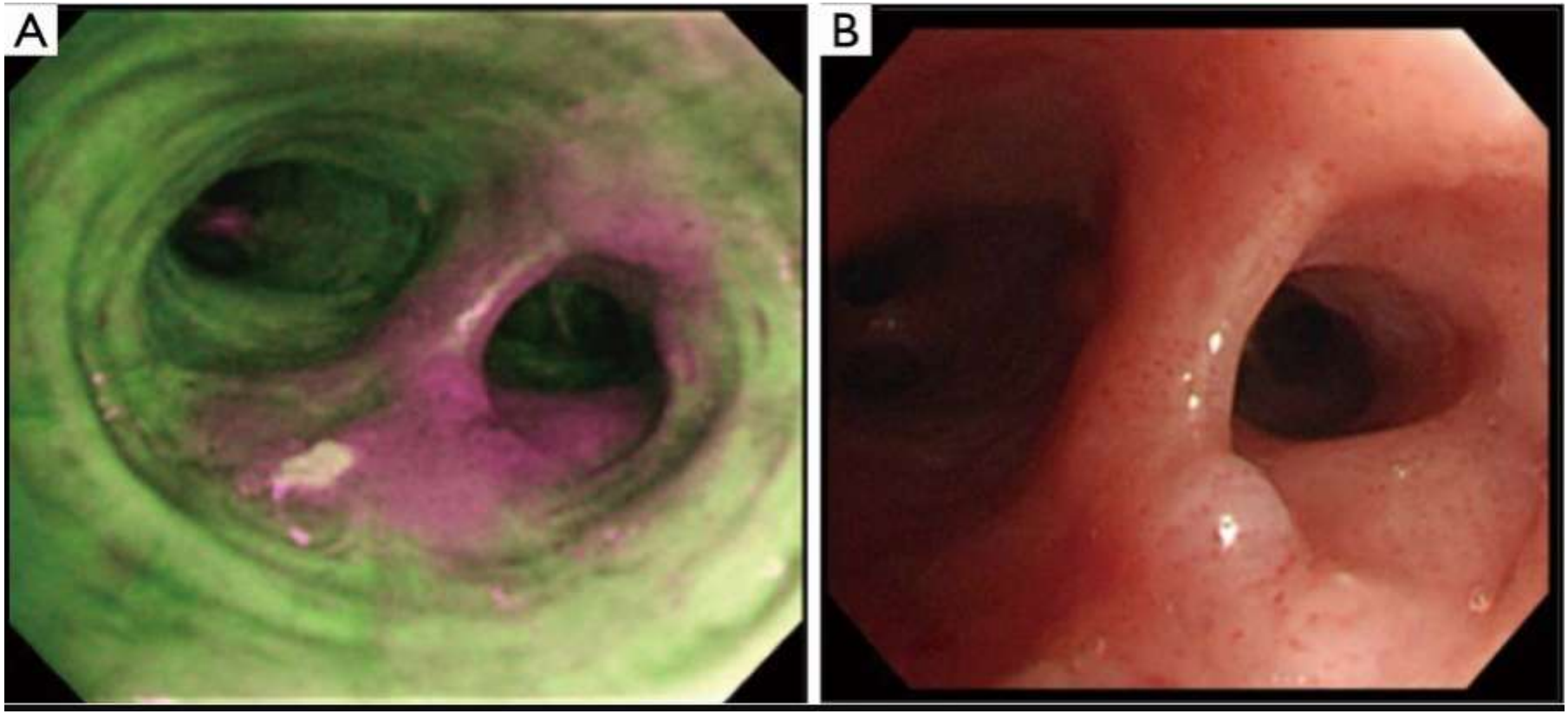

Andolfi M et al J Thorac Dis 2016;8(11):3329

Sun et al JTO 2011

Πρώιμη διάγνωση καρκίνου του πνεύμονα

Detection of lesions

- White light bronchoscopy
- Autofluorescence bronchoscopy
- Narrow band imaging
- Raman spectroscopy

Depth of invasion

- Radial EBUS
- Optical coherence tomography

Narrow Band Imaging (NBI)

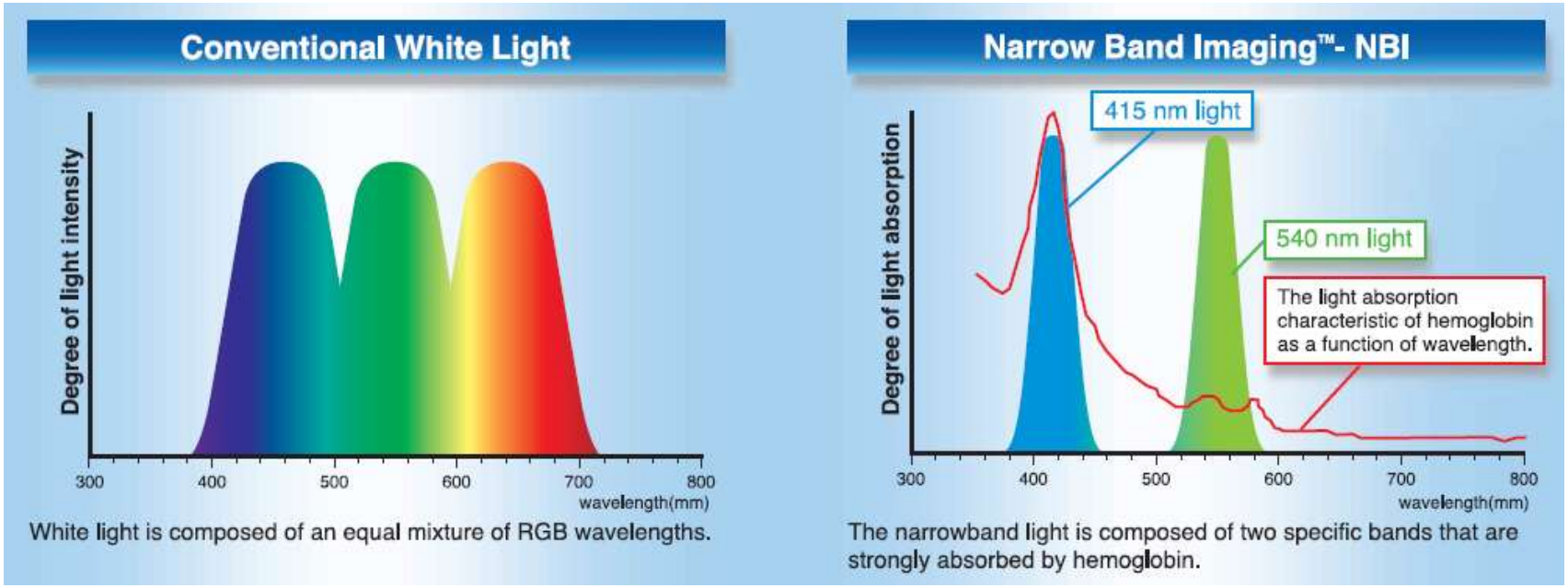

Narrow band imaging

- Superficial vessels (blue light) submucosal vessels (green light)
- NBI vs AFB similar sen / better spe
- NBI + AFB +15,1% spe

Herth J et al JTO 2009
Nguyen et al Head and Neck 2013

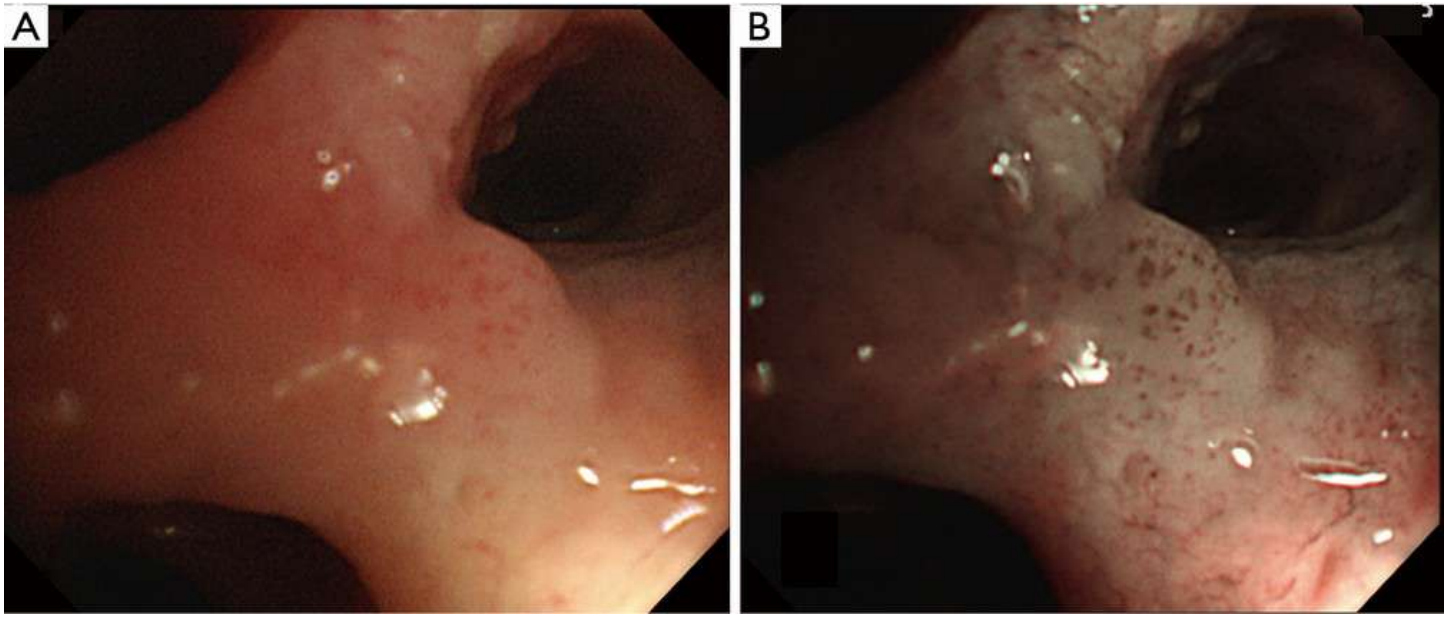

Andolfi M et al J Thorac Dis 2016;8(11):3329

Πρώιμη διάγνωση καρκίνου του πνεύμονα

Detection of lesions

- White light bronchoscopy
- Autofluorescence bronchoscopy
- Narrow band imaging
- Raman spectroscopy

Depth of invasion

- Radial EBUS
- Optical coherence tomography

Using Laser Raman Spectroscopy to Reduce False Positives of Autofluorescence Bronchoscopies

A Pilot Study

Michael A. Short, PhD, Stephen Lam, MD,* Annette M. McWilliams, MD,* Diana N. Ionescu, MD,† and Haishan Zeng, PhD**

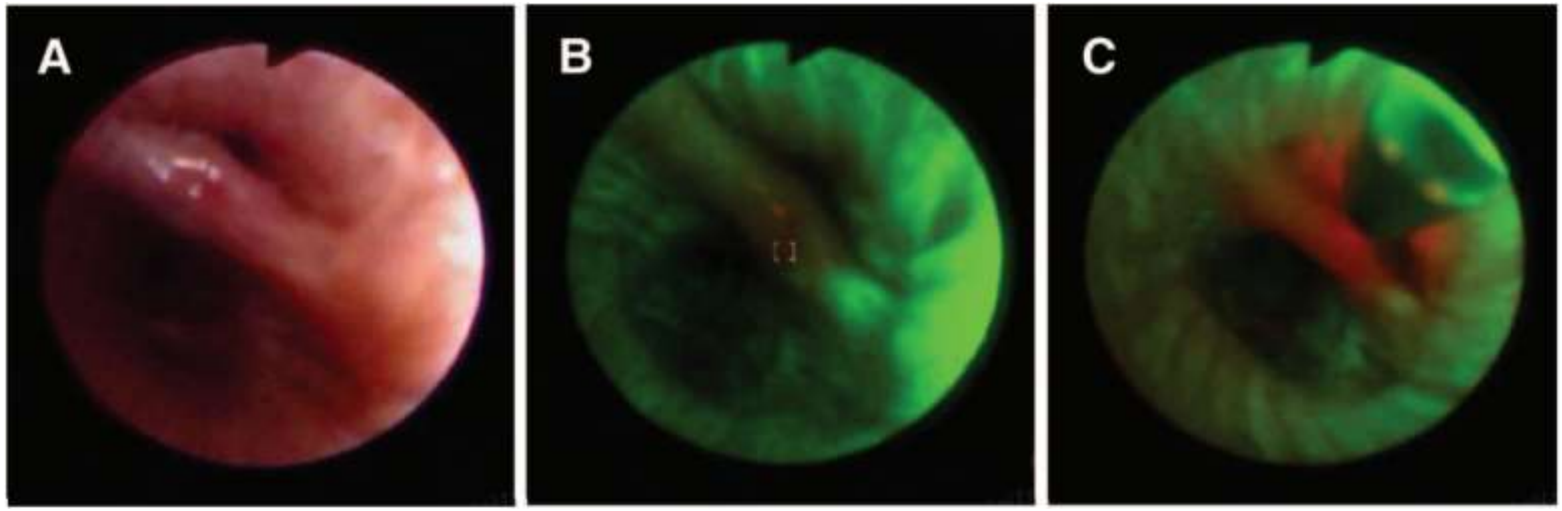

J Thorac Oncol. 2011;6: 1206–1214

Real-time endoscopic Raman spectroscopy for *in vivo* early lung cancer detection

Hanna C. McGregor[1,2], *Michael A. Short*[1], *Annette McWilliams*[1], *Tawimas Shaipanich*[1,4], *Diana N. Ionescu*[3], *Jianhua Zhao*[1], *Wenbo Wang*[1], *Guannan Chen*[1], *Stephen Lam*[1,2,4], *and Haishan Zeng*[*,1,2,3]

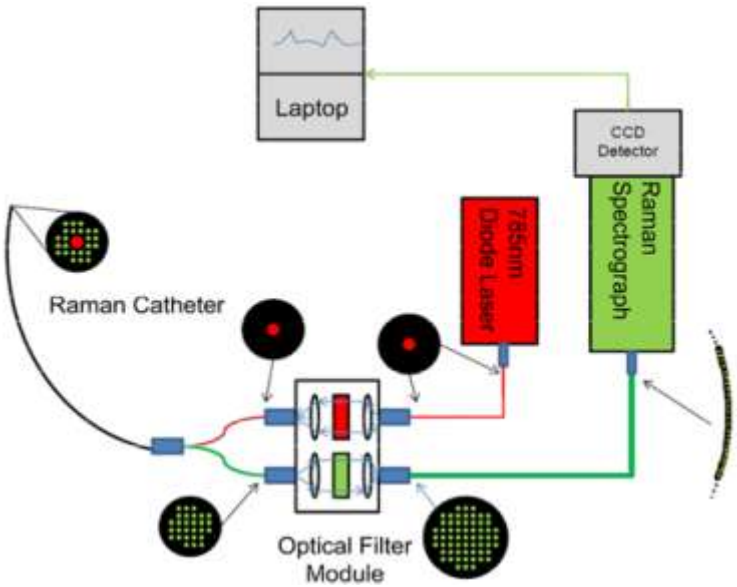

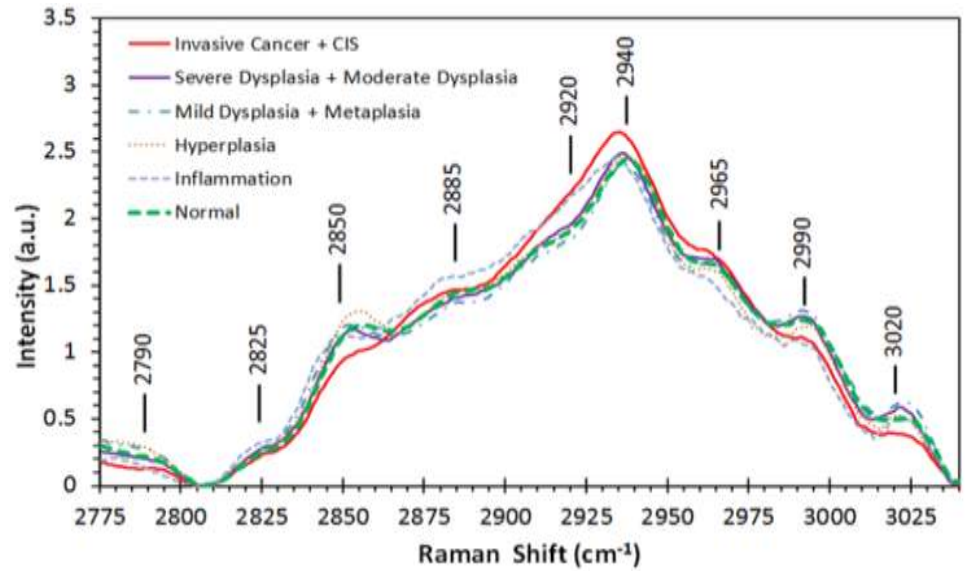

Molecular fingerprinting

J. Biophotonics **10**, No. 1, 98–110 (2017)

Real-time endoscopic Raman spectroscopy for *in vivo* early lung cancer detection

Hanna C. McGregor[1,2], *Michael A. Short*[1], *Annette McWilliams*[1], *Tawimas Shaipanich*[1,4], *Diana N. Ionescu*[3], *Jianhua Zhao*[1], *Wenbo Wang*[1], *Guannan Chen*[1], *Stephen Lam*[1,2,4], *and Haishan Zeng*[*,1,2,3]

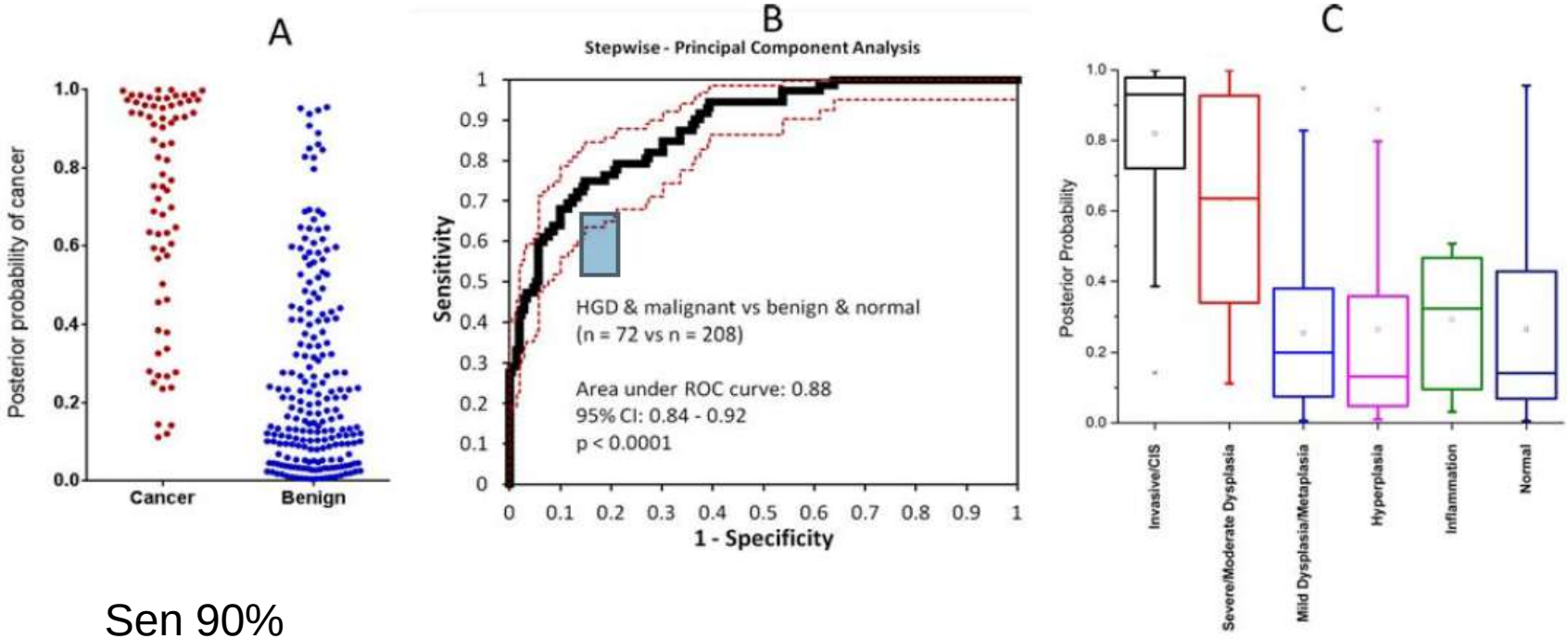

Sen 90%
Spe 65%

J. Biophotonics **10**, No. 1, 98–110 (2017)

Πρώιμη διάγνωση καρκίνου του πνεύμονα

Detection of lesions

- White light bronchoscopy
- Autofluorescence bronchoscopy
- Narrow band imaging
- Raman spectroscopy

Depth of invasion

- Radial EBUS
- Optical coherence tomography

Radial EBUS

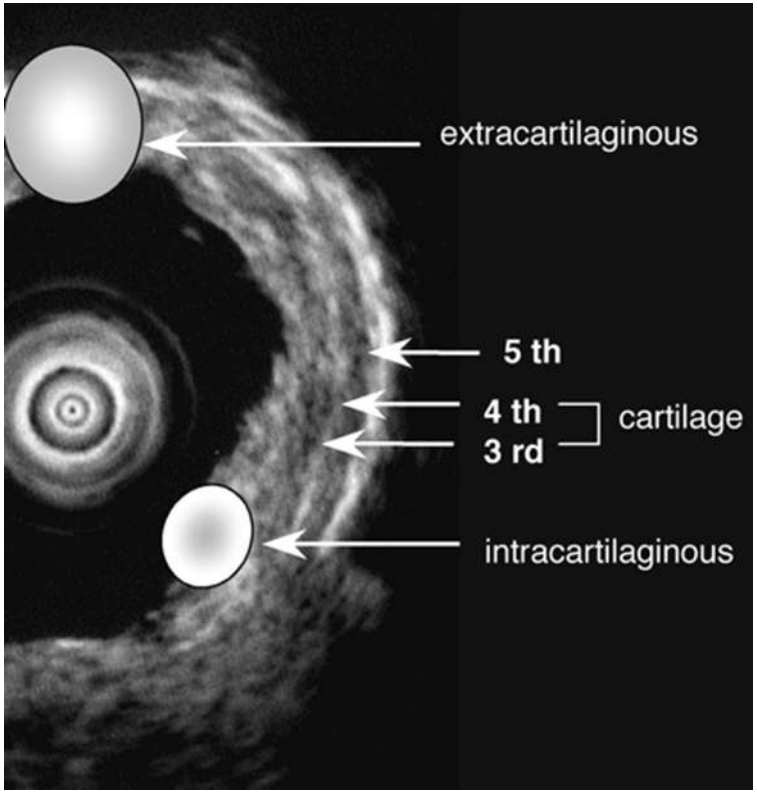

Shirakawa T et al. J Bronchol 2008;15:129-33

Πρώιμη διάγνωση καρκίνου του πνεύμονα

Detection of lesions

- White light bronchoscopy
- Autofluorescence bronchoscopy
- Narrow band imaging
- Raman spectroscopy

Depth of invasion

- Radial EBUS
- Optical coherence tomography

Optical coherence tomography

Ultrasound principle
Near-infrared light
Non-contact probes

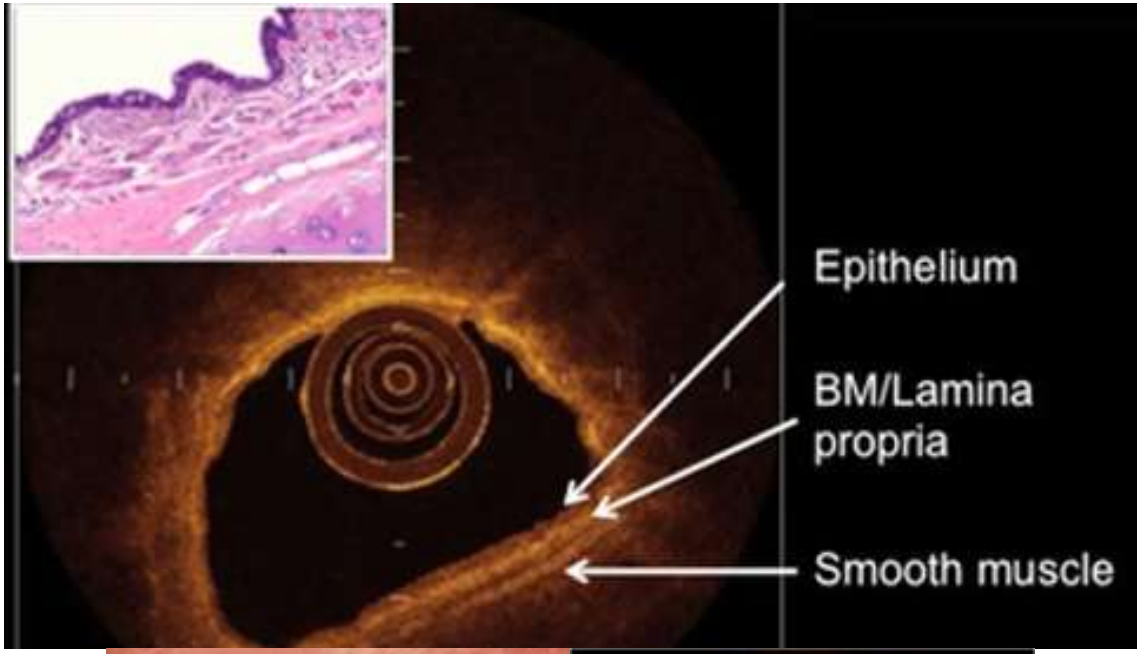

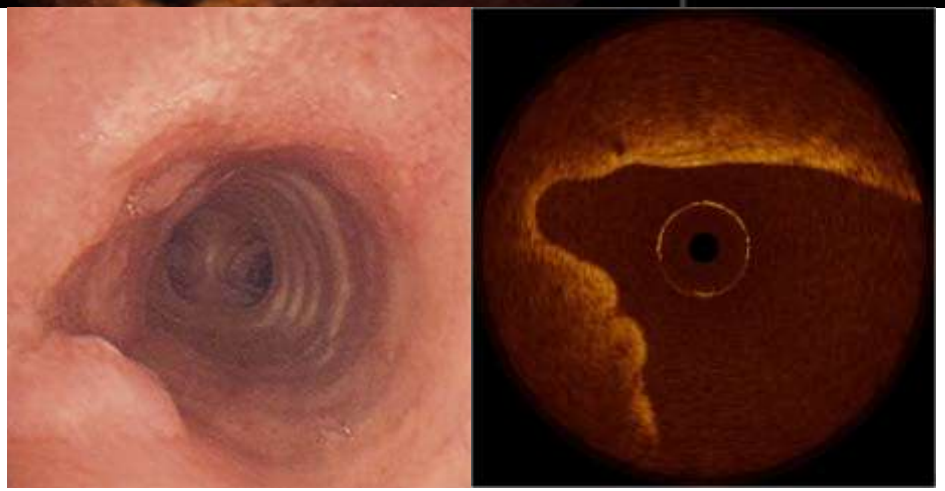

ΑΝΤΙ ΣΥΜΠΕΡΑΣΜΑΤΩΝ

Επαγρύπνηση σε ασθενείς υψηλού κινδύνου

Καλή γνώση αξονικής θώρακα

Αναθεωρημένο TNM

Επικοινωνία με ακτινολόγους, ογκολόγους, ακτινοθεραπευτές, θωρακοχειρουργούς

Ογκολογικά συμβούλια

Στρατηγική λήψης δειγμάτων (θέση, σειρά)

Επικοινωνία με το προσωπικό του βρογχολογικού κέντρου για την κατάλληλη επεξεργασία των υλικών

Ευχαριστώ